

Original Article

Grading of Retinal Hard Exudates by Using VistaView Devise Based on Hybrid Algorithm

Suhair Hussein Talib^{1*}, Osama Qasim¹

¹Department of Electrical Engineering, University of Babylon, Babylon, Iraq.

*Corresponding Author : suhair.yaqoop.engh293@student.uobabylon.edu.iq

Received: 02 April 2024

Revised: 05 May 2024

Accepted: 03 June 2024

Published: 29 June 2024

Abstract - Untreated Diabetic Retinopathy (DR) can lead to different levels of visual impairment and potentially complete loss of eyesight. Undergoing an annual eye examination can be immensely advantageous in identifying prospective visual impairments, particularly for individuals with diabetes, aiding in preventing early-stage vision deterioration. Due to technological improvements, retinal imaging technologies for cell phones are now commercially available. The remarkable feature of retinal imaging systems is their capacity to conduct cost-effective and efficient screening for diabetic retinopathy in diverse settings. Nevertheless, the accuracy of DR detection can be influenced by the area of view and image quality. Due to their small size, smartphone-based retinal imaging plans typically produce images of inferior quality and have a narrower field of vision than traditional fundus cameras. The goal of this study is to thoroughly examine several approaches to handling retinal images in the field of ophthalmology in order to identify and assess the degree of abnormalities. The research endeavors to obtain retinal images with cutting-edge imaging technologies such as the Vista view. On the other hand, fundus cameras are too expensive and heavy for most health clinics to buy and transport. Thus, compact, portable, and reasonable retinal imaging technologies for quick DR screening are needed. Every health clinic cannot afford fundus cameras, which are bulky and cumbersome. Thus, quick DR screening retinal imaging systems that are tiny, portable, and affordable are in demand. Then examined the view field of commercial smartphone-based portable ophthalmoscope systems to assess whether they are acceptable for DR screening during a general health exam. The Vistaview retinal imaging system has better image quality and an extensive field of view than other devices. It then makes use of a variety of image-enhancing algorithms to raise the photographs' quality and clarity. The researchers investigated the effectiveness of MRLS, a multi-level rhombus segmentation method, for identifying lesions in retinal images caused by conditions like diabetic retinopathy and macular degeneration. This method uses median filters and morphological processes to identify anomalies automatically. The assessment of lesions created on their severity and progression is another area of investigation in this study. In order to do this, an Artificial Neural Network (ANN) system based on the ANN's Delta Learning Rule (DLR) is proposed. The resolve of this system is to identify images and control whether a dangerous situation is present. This work is a significant step towards the development of reliable and effective methods for the prompt diagnosis and treatment of retinal disorders.

Keywords - VistaView, Diabetic Retinopathy (DR), MRLS, Median filter, DLR.

1. Introduction

Damage to the eyes can result from a variety of ailments. Diabetic Retinopathy (DR) is an optical condition characterized by lesions in the eye that may lead to blood vessel damage and subsequent visual impairment or even blindness. Examining the retina helps lessen the effects of eye conditions. Moreover, people with diabetes need to regularly take a digital image of their retina.

The International Diabetes Federation reports that there are 463 million individuals aged 20 to 79 who have diabetes. Diabetic Retinopathy (DR) is assessed by examining the retinal fundus. DR grading schemes include the Early Treatment Diabetic Retinopathy Study (ETDRS). Damage to

the blood vessels in the retina results in retinal abnormalities, which are a significant contributor to blindness in individuals between the ages of 20 and 60. The occurrence of haemorrhages and microaneurysms can serve as early indications of Diabetic Retinopathy (DR).

The modern era has witnessed an unprecedented rise in the application of technology in the health sector. In order to enhance the quality of care that is accessible to individuals in various parts of the world, specialists in the field of ophthalmology have continuously been looking forward to integrating the most modern technology into their medical processes. Handheld retinal cameras have turned out to be an emergent and efficient tool for preventing blindness. The



development of such devices has made retinal imaging much more accessible, which is extremely important for detecting and treating eye disorders like diabetic retinopathy and glaucoma. Through the use of handheld retinal devices, mass screening and diagnosis in primary care facilities can be done with the objective of managing and treating any upcoming cases. This is due to the fact that these devices provide an economic, rapid, and effective means of early detection of subclinical retinal pathology in a large adult population [1].

Cameras and imaging devices nowadays can connect wirelessly anywhere and to any hardware. On the other hand, mobile and wireless technology can make such a network more efficient and helpful for the patient and the doctor. However, it is still very unexplored and innovative work. It can be used in hospitals and any other place without the need for further technology, improving the diagnosis rate. This will allow for a faster and more effective transition from laboratory methods to clinical practices; in this way, the public health sector can take advantage of the new developments implementing them for the best [2].

Doctors frequently examine and physically classify ocular disorders, such as Red Lesions (RLs), Soft Exudates (SEs), and Hard Exudates (HEs), as illustrated in Figure 1. However, manual detection is a time-consuming procedure that is liable to observer error. It takes a lot of time and effort to do a manual examination. For a very long time, ophthalmologists have been performing manual diagnosis and analysis.

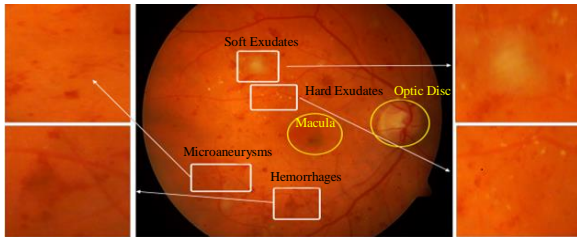


Fig. 1 The fundus photos of an eye with maculopathy showcase haemorrhages, soft exudates, hard exudates, and microaneurysms

This work aims to describe the main technological aspects of these devices, with a particular focus on image capture. Here, the capabilities of VistaView are examined and improved by creating and testing new methods to understand and diagnose retinal diseases more effectively. This will give an opportunity to a larger portion of the population that suffers from common diseases, such as diabetes, which can cause severe eye problems, such as diabetic retinopathy.

It solves many problems because it is considered a device compared to other ophthalmic devices. It is small in size, can be carried by hand, and is light in weight. It can be carried anywhere, especially in remote rural areas, and its price is appropriate. Automated eye screening technologies can be

useful in quickly and accurately identifying warning signs of various retinal issues. Thus, numerous images of a comparable patient are examined at different points in time, and the results are contrasted to monitor the development of an already-existing illness or search for early warning signs of a developing one. One method to assist in this is the early automated detection and grading of different types of retinal lesions associated with the DR.

2. Literature Survey

Several techniques were proposed to detect DR, as presented in the following survey. Some devices are used to take pictures of the retina.

Yung et al. [3] state that the diagnosis of Diabetic Retinopathy (DR) typically involves capturing Optical Coherence Tomography (OCT) with digital fundus images. Given the high cost of OCT equipment, it would be beneficial for both patients and ophthalmologists to achieve an appropriate diagnosis solely through the examination of fundus digital pictures. The study offers a brand-new approach built on a Deep Convolutional Neural Network (DCNN). In contrast to the conventional DCNN method, we substitute fractional max-pooling for the widely-used max-pooling layers. For classification, we train two Deep Convolutional Neural Networks (DCNNs) with different numbers of layers to extract more unique features.

Petteri et al., [4] the field of ophthalmology has recently shown great interest in deep learning because of its capacity to identify important traits for diagnosing and predicting the progression of diseases. Despite notable advancements, the understanding of how different deep learning systems can integrate into ophthalmic imaging devices for automated picture acquisition remains limited.

Hossein et al., [5] utilized a handheld lens. An optical system akin to ophthalmoscopy is achieved by combining smartphone retinal imaging, a coaxial flashlight from the smartphone camera, and a portable high-plus power lens. Digital retinal pictures with great resolution can be obtained with this technology.

Das et al. [2] when taking images, the focus was directed towards the posterior pole, including the optic disc and macula. The researchers directed the participants to evaluate the overall comfort of each imaging modality's examination using a 10-point Likert scale. They were asked to consider flash intensity, equipment proximity, and test time.

However, Silke et al., [6] found that cross-sectional images of the tissue structure can be obtained by employing a scanning OCT beam. The axial resolution, imaging range, and technological implementation of the characteristics of the light source and detector define the OCT system.

Young et al., [7] shown Laser Ophthalmoscopes with Adaptive Optics-Scanning (AOSLO). The simulation includes light-sensitive cells that organize themselves, the eye movements of the observer during image capture, and data collecting through a realistic system that accounts for noise, optical aberrations, and diffraction. Also, Y. Yang et al., [8] created a two-step algorithm using Deep Convolutional Neural Networks (DCNN) that can both find problems in fundus images and figure out how bad Diabetic Retinopathy (DR) is. Deep Convolutional Neural Networks (DCNNs) with two stages can learn more about the deep features of fundus pictures to help with the global and local analysis of Diabetic Retinopathy (DR).

Songhua et al. [9] the FCM method may efficiently identify the global optimum by utilizing the estimated answer as its initial value. This has been verified by empirical evidence in the segmentation of retinal vascular images employing morphological filtering introducing a new segmentation approach that combines evolutionary algorithms with FCM fuzzy clustering algorithms. They employ the initial genetic algorithm to acquire an approximate solution for the global optimum.

Malhy introduces a simple and successful diabetic retinopathy screening method [10]. This empirical research method uses fundus camera-captured colored images from public databases. Exudates and microaneurysms in fundus pictures are used to grade diabetic retinopathy. This grading system classifies conditions as mild, moderate, or severe. Using image analysis, feature recognition, and machine learning techniques, exudates and microaneurysms can be accurately predicted. Exudates are measured from the macula, whereas microaneurysms are counted.

The O-shaped neural network created by Zhang et al., [11] incorporates attention modules and does not depend on segmentation for the purpose of identifying junctions in biological images. The system consists of two branches: a local enhancement branch and a junction detection branch. These branches are responsible for the identification of junctions, the collection of contextual information, and the incorporation of local features.

In their scientific publication, our previous study present a method for the detection of diabetic retinopathy retinal lesions. Both low and high saturation levels are present in the data of this study, and the authors make adjustments to the numbers to make them more contrasty. Using a rhombus multi-level algorithm, the study introduces a new way to segment retinal images. Gradient algorithms, median filters, morphological operations, segmentation, and preprocessing are all part of the proposed approach. A highly efficient automated system is created by combining these components.

Furthermore, a study conducted by Palavalasa et al. [12] investigated the application of image processing methods to fundus images obtained from the DiaretDb database with the objective of identifying yellow lesions. To increase the contrast of the fundus images and facilitate object recognition, the researchers transformed them into green channels.

Zhixi et al. [14] carried out a study to evaluate the degree of agreement between a deep learning system, general ophthalmologists with varying degrees of clinical competence, and non-physician graders in recognizing diabetic retinopathy that can be referred.

Zhou et al. [15] use a technique known as superpixel multi-feature classification to explain the process of automatically identifying exudates. The process commences by dividing the entire image into multiple superpixels, subsequently identifying these as potential candidates. We recommend a total of 20 elements, consisting of 19 multichannel intensity features and a novel contextual feature, to describe each candidate. We propose a supervised multivariable classification algorithm to differentiate authentic exudates from counterfeit candidates.

3. Retinal Devices

Various imaging techniques, including Optical Coherence Tomography (OCT), fundus pictures, fluorescein angiography, scans, and ultrasound, have generated retinal datasets in the field of clinical optometry. OCT detects vascular anomalies in the retina [16], whereas fundus images capture the internal buildings of the retina, such as the optic disc, macula, and blood vessels. We use fluorescein angiography to detect blood vessel leakage in the retina. There are two techniques available for acquiring fundus images. An effective process for obtaining the fundus picture involves the use of tropicamide (eye drops) to dilate the retina, resulting in the production of the image known as mydriatic fundus imaging. Additionally, you can take the fundus picture concurrently by using a direct ophthalmoscope. Volk's refers to these devices [17].

VistaView is employed in this study for the collection of retinal pictures. Volk's latest product integrates photography and data administration into a single device. The Vista View combines the capabilities of Volk optics with the convenience, portability, and cost-effectiveness of smartphone technology, enabling widespread access to and possession of a high-quality, portable, mydriatic retinal camera. The VistaView not only fits conveniently in your bag but it is specifically intended to align with and improve your workflow, allowing you to efficiently attend to a larger number of patients and optimize your effectiveness. LK states that the VistaView has a view field of 55°, which is regarded as the broadest among all mydriatic fundus cameras in its category.

The device offers a voice capture feature for operating without using hands; it has both autofocus and manual imaging modes; it allows modification of illumination for patients who are sensitive to light and have different pigments in their retina; and it enables the sharing of password-protected reports and DICOM pictures for invoicing, consultation, or referral purposes. The pricing is reported to be lower than that of standard desktop fundus cameras while maintaining the same level of image quality. The gadget is shown in Figure 2 [18, 19].




Fig. 2 VistaView device

3.1. VistaView Specifications Can be Explained as Follows [18, 19]

- Red-free filter to enhance the visibility of blood vessels.
- USB-C charging eliminates the need for external batteries.
- Transfer data to a computer using a USB-C connection. Transfer your files to your computer by dragging and dropping them.
- Rapid creation of reports with case notes allows quicker attendance at the next patient.
- Export DICOM files to seamlessly link patient pictures with your EMR system.
- Enable password-protected data export to enhance security while sharing data.
- Utilize on-board patient data search and sorting to manage all patient data in a centralised location efficiently.
- The camera can automatically focus subjects, as well as the option to manually adjust the focus with a range of -15D to +15D. Select your desired level of authority.
- Adjust the illumination to high, medium, or low settings to ensure patient comfort. A white LED light serves as the light source for the mydriatic fundus camera. It has a storage capacity of 128 GB.
- The camera has a resolution of 31 pixels per degree.
- The external dimensions are 88 x 202 x 103 mm.
- The camera weighs 560 grams.
- It comes with a one-year warranty.

3.1.1. Recruitment and Subsequent Data Collection

The medical images were obtained from the Center for Medical Sciences for Ophthalmology, as shown in Figure 3, and we are seeking to analyze and interpret these images for diagnostic purposes.



Fig. 3 The picture of a medical science center for ophthalmology

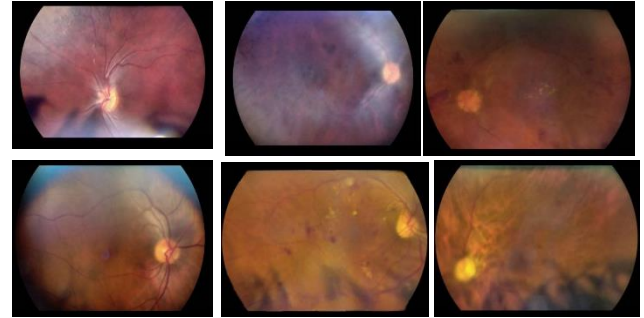


Fig. 4 Pictures taken with the VistaView device

4. Proposed Method

Early screening can help prevent the lesions found in the retina, which is a significant sign of Diabetic Retinopathy (DR). Several extant works for detecting HE(s) are described in the literature, especially [2]. Therefore, this work can benefit from their idea to grade the lesions that are detected. Here, the device that is used for image acquisition is VistaView. Figure 5 illustrates the schematic representation of the entire proposed system. The play emphasizes the primary goal of this investigation. The objective is to develop a method for capturing, automatically detecting, and evaluating the performance of a portable gadget called Drin One.

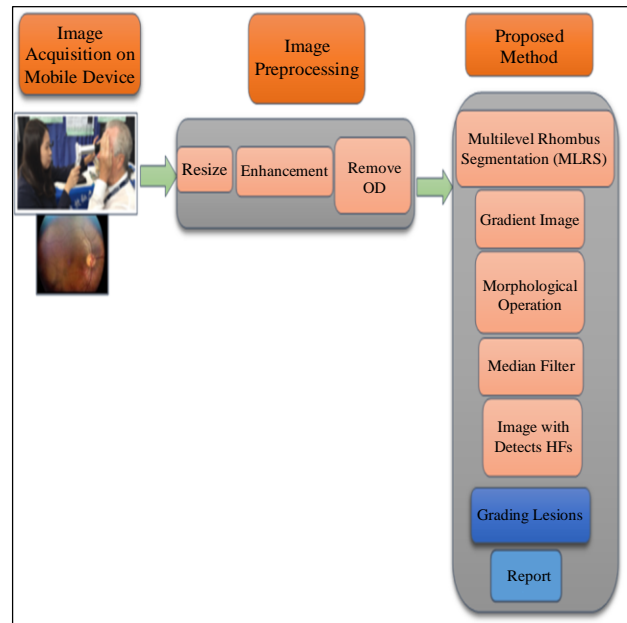


Fig. 5 The block diagram of the proposed technique, which highlights the presence of brilliant elements

4.1. Image Processing

Image processing enhances image quality by eliminating extraneous details and noise. This improves the accuracy of feature extraction and grading tasks, especially when crucial data is collected utilizing suitable processing methods. Precise identification of the macula is essential for grading, as the proximity of the exudates to the macula is a determining factor. The macula is located in an area with extremely low vascular density. In addition, the algorithm identifies the distance between the optic disc and the lowest point of darkness in the central area of the macula. The green channel is separated from the original colored images, enhancing the contrast. The green channel exhibits lower saturation compared to the blue channel, allowing for clearer and more distinct visualization of lesions and other objects compared to the red channel. Contrast enhancement is effective in detecting hard exudates, as they are well separated from the background.

In this work, adjusting the lighting and composition can definitely help achieve a more balanced and attractive image. Various filters and settings are available in your smartphone to find the perfect combination for resizing an image, preprocessing it, and then inputting it into a program. To achieve this, you can use a tool or software that can read the image, resize it, apply any necessary preprocessing steps, and then pass it into the desired program. In addition, different masks for left and right images are used for adjusting images. These steps are taken to ensure that the threshold used in the algorithm is automatically applied to any input image. This automation can help with the processing steps, which can be summarized as follows: streamline the process and ensure consistency.

1. Downsize the fundus photos to a standardized dimension of 480x640 pixels.
2. Green Channel Extraction: Transform the fundus images, initially in RGB format, into their corresponding green channels.
3. To ensure accurate identification and localization of exudates, it is imperative to detect and clear the optic disc, as it exhibits an intensity level similar to that of exudates.
4. A rhombus is a geometric figure with four equal sides and equal opposite angles. Image analysis and computer vision both rely heavily on segmentation. This system precisely detects and extracts rhombus-shaped objects from images. You must separate the rhombus formation borders from the background to complete this task. Rhombuses can be classified or measured using particular parameters. Edge recognition, contour tracing, and geometric shape fitting can divide a rhombus exactly. Reference [9] has more details.
5. The median filter is widely used and provides good results in medical image processing. The method successfully eliminates distracting visual elements from photos without losing any of the important medical facts. Filtering out noisy pixels and replacing them with the

median values of nearby pixels enhances picture quality and reduces noise.

6. Medical image processing uses the median filter effectively. The method minimizes visual disruptions from photos while keeping medical picture details. The filter effectively reduces noise and enhances image quality by replacing pixel values with neighboring medians.
7. Medical image processing uses the median filter effectively. The method minimizes visual disruptions from photos while keeping medical picture details. The filter effectively reduces noise and enhances image quality by replacing pixel values with neighboring medians.

5. Materials

The pictures in the dataset were used to train a new auto-detection method for retinal images taken with the VistaView device. There was also testing of this method using the same set of data. The captured photos have a field of view of 5 degrees and a resolution of 31 pixels per square degree. Out of these photographs, 15 of them have lesions of different sorts.

6. Results and Discussion

Most retinal images may have poor visual contrast and are not evenly illuminated. A few pre-processing steps were taken to enhance the image quality. The input consists of a fixed size of 480*640, and the color image is a green channel. Since some of the images in this piece seemed darker and others were lighter, we scaled the photos by a specified ratio to enhance contrast by increasing the brightness of specific areas relative to others. Subsequently, eliminate the optic disk.

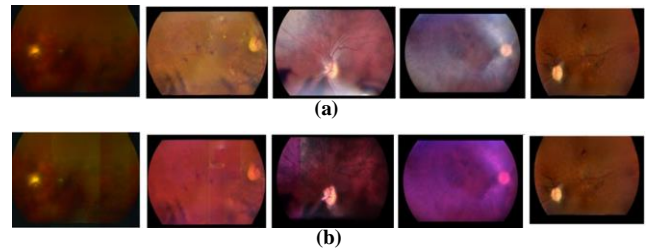


Fig. 6 (a) Before preprocessing, and (b) After preprocessing.

Several steps are taken to get rid of OD, and they can be summarized as follows:

- Transform the image into a binary image by applying Otsu's thresholding technique.
- For the binary image, apply morphological closing with a 10-radius disk-shaped structural element.
- Utilize the canny edge-detecting algorithm.
- Compute the radius of the OD mask by using the circle equation and determining since the OD has the highest intensity value, the maximum pixel value for the image's intensity.

- To prevent any mistake between Optical Density (OD) and Hematoxylin-Eosin (HE) stains, it is a good idea to find the image's average backdrop intensity. As a result, there will be more consistency in the OD mask's hue. What hue is the background? Figure 7 illustrates the steps involved in photo preprocessing and removing the optic disk using a neighborhood operation.
- Colfilt computes the variance, exhausting.

VistaView images, after preprocessing and OD removal, are entered into segment algorithms (rhombus), as shown in Figure 8.

6.1. Grading Result

In this work, it is found that the exudate is considered to be an affected lesion when its area is more than 5 pixels in the

image taken (480 x 640) for the test. You can see the detection of exudates by the proposed system and circular grading in Figure 9 for both left and right images. Here, four cases are tested so that the circular grading is taken on the color image, and the detected exudates are mentioned in yellow. Table 1 shows the tested images with their lesions distributed across three regions: the fovea region, the first circle, and the second circle. This operation configures the retina image for diagnosis by using an intelligent algorithm, and here, the delta neural network is chosen.

This decision is taken when there are exudates in the fovea region, irrespective of whether there are existing exudates in the region or not. The diagnosis of these exudates by the Delta Learning Rule (DLR) of ANN for 15 images is shown in Table 2 (Shown in Appendix).

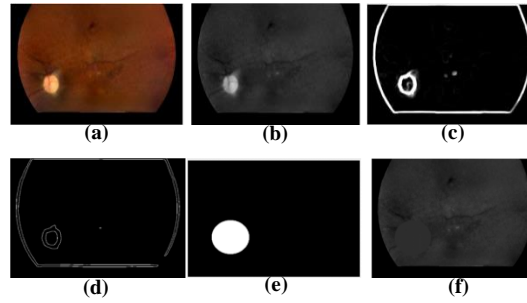


Fig. 7 Many preprocessing procedures. The picture will undergo the following operations: (a) Contrast Limited Adaptive Histogram Equalization (CLAHE), (b) Color Filtering (Colfil), (c) Morphological Closing, (d) Canny edge detection, (e) Creation of a mask for the Optic Disc (OD), and (f) Application of the mask on the retinal image.




Fig. 8 The results of the right image. (a) The RGB image is preprocessed, (b) - (c) The green image is obtained by eliminating the Optical Density (OD), (d)-(h) The first, second, third, fourth, and fifth segmentations are shown, (i) Represent the gradient image, and (j) Shows the image after applying a median filter.

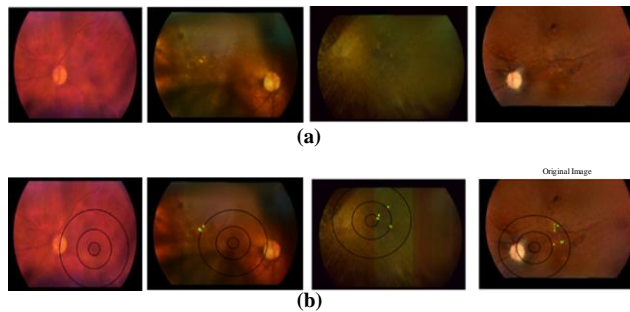


Fig. 9 Detects and grade for HE (a) Retina color images, and (b) Their HE detection results by the proposed methods and circular grading.

Table 1. Number of lesions (pixels)

Number of Lesions (Pixels)					
Patient		Center (Urgent)	Region 1 (Moderate)	Region 2 (Mild)	Region 3 (Normal)
Name	Age				
Abass Ali	33	0	14	0	0
Amer Alywe	26	0	0	706	715
Fatima Gzar	75	0	0	95	0
Halima Saheb	58	8	51	49	0
Hussein Talib	59	0	0	0	0
Kudara Kudair	65	0	0	0	366
Sadia Salim	44	0	0	0	311
Qasim Hasan	63	0	0	497	110
Sebeha	45	0	0	12	122
Hadia Merdan	70	0	0	0	166
Ihsan Mazher	19	0	0	0	0
Saher Abed	50	0	0	0	0
Mohammed Najam	47	0	0	0	0
Fareed Abed	54	0	0	0	0
Alyaa Mohammed	17	0	0	0	817

7. Conclusion

The VistaView is a portable device that is highly convenient to transport, particularly in nursing homes or for individuals with disabilities who are unable to sit at a slit lamp. The images are well-defined and sharp, providing an approximate field of vision of 55°. For data protection, it also enables the user to encrypt the photos that are taken using a password key. By doing this, emailing the retinal scans is made even more secure. Technologies based on retinal imaging from smartphones can replace the eyepiece directly. However, the precision of automatic DR detection is significantly impacted by the field of view of smartphone-based retina imaging sensors.

The need in medicine for efficient instruments to measure various kinds of lesions in retinal pictures served as the driving force behind the development of the suggested technique. Because retinal lesions vary in shape and appearance among patients, as well as because images are not uniformly bright, accurately detecting retinal lesions is a difficult task. The key to achieving design success lies in selecting an appropriate image for the purpose of detecting High Explosives (HE) after undergoing certain preprocessing procedures. In addition, the grading of lesions based on severity and progression using

delta learning algorithms has enabled precise classification and risk stratification of retinal diseases. This has led to personalized treatment plans and improved patient. The discussion: Lesion identification is presented as an easy-to-use yet effective integrated approach. It integrates several preprocessing methods with MLRS and a median filter, followed by post-processing steps.

When used logically and sequentially, these methods provide a quick and highly effective means to distinguish between different lesions of any texture, shape, size, outcome, etc. It can be concluded from the result that the circular grading is very good at specifying the lesion area and the damage level. Overall, the integration of capturing images, enhancement, lesion detection algorithms, and lesion grading techniques in retinal imaging has paved the way for more efficient, accurate, and personalized care for patients with retinal disorders.

Acknowledgments

I want to acknowledge the Medical Science Center for Optometry for their effective assistance in allocating sufficient time for the purpose of taking retinal images of the patients in the center.

References

- [1] Ramachandran Rajalakshmi et al., "Review of Retinal Cameras for Global Coverage of Diabetic Retinopathy Screening," *Eye*, vol. 35, pp. 162-172, 2021. [[CrossRef](#)] [[Google Scholar](#)] [[Publisher Link](#)]
- [2] Susmit Das et al., "Feasibility and Clinical Utility of Handheld Fundus Cameras for Retinal Imaging," *Eye*, vol. 37, pp. 274-279, 2023.
- [3] Yung-Hui Li et al., "Computer-Assisted Diagnosis for Diabetic Retinopathy Based on Fundus Images Using Deep Convolutional Neural Network," *Mobile Information Systems*, 2019. [[CrossRef](#)] [[Google Scholar](#)] [[Publisher Link](#)]
- [4] Petteri Teikari et al., "Embedded Deep Learning in Ophthalmology: Making Ophthalmic Imaging Smarter," *Therapeutic Advances in Ophthalmology*, vol. 11, pp. 1-21, 2019. [[CrossRef](#)] [[Google Scholar](#)] [[Publisher Link](#)]
- [5] Hossein Nazari Khanamiri, Austin Nakatsuka, and Jaafar El-Annan, "Smartphone Fundus Photography," *Medicine*, pp. 1-5, 2017. [[CrossRef](#)] [[Google Scholar](#)] [[Publisher Link](#)]
- [6] Silke Aumann et al., "Optical Coherence Tomography (OCT): Principle and Technical Realization," *High Resolution Imaging in Microscopy and Ophthalmology*, pp. 59-85, 2019. [[CrossRef](#)] [[Google Scholar](#)] [[Publisher Link](#)]
- [7] Laura K. Young, and Hannah E. Smithson, "ERICA: Emulated Retinal Image Capture - A Tool for Testing, Training and Validating Retinal Image Processing Methods," *bioRxiv*, pp. 1-15, 2021. [[CrossRef](#)] [[Google Scholar](#)] [[Publisher Link](#)]
- [8] Yehui Yang et al., "Lesion Detection and Grading of Diabetic Retinopathy via Two-Stages Deep Convolutional Neural Networks," *Medical Image Computing and Computer Assisted Intervention (MICCAI)*, pp. 533-540, 2017. [[CrossRef](#)] [[Google Scholar](#)] [[Publisher Link](#)]
- [9] Songhua Xie, and Hui Nie, "Retinal Vascular Image Segmentation Using Genetic Algorithm Plus FCM Clustering," *2013 Third International Conference on Intelligent System Design and Engineering Applications*, Hong Kong, China, pp. 1225-1228, 2013. [[CrossRef](#)] [[Google Scholar](#)] [[Publisher Link](#)]
- [10] Avleen Malhi, Reaya Grewal, and Husanbir Singh Pannu, "Detection and Diabetic Retinopathy Grading Using Digital Retinal Images," *International Journal of Intelligent Robotics and Applications*, vol. 7, pp. 426-458, 2023. [[CrossRef](#)] [[Google Scholar](#)] [[Publisher Link](#)]
- [11] Yuqiang Zhang et al., "An O-Shape Neural Network with Attention Modules to Detect Junctions in Biomedical Images without Segmentation," *IEEE Journal of Biomedical and Health Informatics*, vol. 26, no. 2, pp. 774-785, 2022. [[CrossRef](#)] [[Google Scholar](#)] [[Publisher Link](#)]
- [12] Kranthi Kumar Palavalasa, and Bhavani Sambaturu, "Automatic Diabetic Retinopathy Detetion Using Digital Image Processing," *2018 International Conference on Communication and Signal Processing (ICCSP)*, Chennai, India, pp. 0072-0076, 2018. [[CrossRef](#)] [[Google Scholar](#)] [[Publisher Link](#)]
- [13] Harini R., and Sheela N., "Feature Extraction and Classifcation of Retinal Images for Automated Detection of Diabetic Retinopathy," *2016 Second International Conference on Cognitive Computing and Information Processing (CCIP)*, Mysuru, India, pp. 1-4, 2016. [[CrossRef](#)] [[Google Scholar](#)] [[Publisher Link](#)]
- [14] Zhixi Li et al., "Using Deep Leaning Models to Detect Ophthalmic Diseases: A Comparative Study," *Frontiers in Medicine*, vol. 10, pp. 1-11, 2023. [[CrossRef](#)] [[Google Scholar](#)] [[Publisher Link](#)]
- [15] Wei Zhou et al., "Automatic Detection of Exudates in Digital Color Fundus Images Using Superpixel Multi-Feature Classification," *IEEE Access*, vol. 5, pp. 17077-17088, 2017. [[CrossRef](#)] [[Google Scholar](#)] [[Publisher Link](#)]
- [16] Dimple Nagpal et al., "A Review of Diabetic Retinopathy: Datasets, Approaches, Evaluation Metrics and Future Trends," *Journal of King Saud University - Computer and Information Sciences*, vol. 34, no. 9, pp. 7138-7152, 2022. [[CrossRef](#)] [[Google Scholar](#)] [[Publisher Link](#)]
- [17] Dimple Nagpal et al., "Recent Advancement for Diagnosing Diabetic Retinopathy," *Journal of Computational and Theoretical Nanoscience*, vol. 17, no. 11, pp. 5096-5104, 2020. [[CrossRef](#)] [[Google Scholar](#)] [[Publisher Link](#)]
- [18] Review of Optometry, Handheld Retinal Camera Allows On-the-Go Imaging, Volk's Newest Combines Photography and Data Management in One Device, 2020. [Online]. Available: <https://www.reviewofoptometry.com/article/handheld-retinal-camera-allows-onthego-imaging>
- [19] Volk, VistaView™ – Volk Optical. [Online]. Available: <https://www.volk.com/pages/vistaview%E2%84%A2>

Appendix

Table 2. Grading image

Patient Image	Grading Image Phone				Outcome Decision of Doctor
	Normal	Mild	Moderate	Urgent	
Abass Ali	NO	NO	YES	NO	Patient case: Moderate Doctor decision: Rescreening after six months
Amer Alawye	YES	YES	NO	NO	Patient case: Mild Doctor decision: Annual screening
Fatima Gzar	NO	NO	YES	NO	Patient case: Mild Doctor decision: Annual screening
Halima	YES	YES	YES	NO	Patient case: Urgent Doctor decision: Referred the hospital and remain him under surveillance
Hussein Talib	NO	NO	NO	NO	Patient case: Normal Doctor decision: The decision is not to worry
Kudera Khudair	YES	NO	NO	NO	Patient case: Normal Doctor decision: The decision is not to worry
Sadia Salim	YES	NO	NO	NO	Patient case: Normal Doctor decision: The decision is not to worry
Qasim Hasan	YES	YES	NO	NO	Patient case: Mild Doctor decision: Annual screening
Sebeha	YES	YES	NO	NO	Patient case: mild Doctor decision: Annual screening
Hadia Merdan	YES	NO	NO	NO	Patient case: Normal Doctor decision: The decision is not to worry
Ihsan Mazher	NO	NO	NO	NO	Patient case: Normal Doctor decision: The decision is not to worry
Saher Abed	NO	NO	NO	NO	Patient case: Normal Doctor decision: The decision is not to worry
Mohammed Najam	NO	NO	NO	NO	Patient case: Normal Doctor decision: The decision is not to worry
Fareed Abed	NO	NO	NO	NO	Patient case: Normal Doctor decision: The decision is not to worry
Alyaa Mohammed	YES	NO	NO	NO	Patient case: normal Doctor decision: The decision is not to worry