

Diabetes Insipidus in Sepsis

¹Dr. S.Theophilus Ved Bhushan M.S. FAIS, ²Dr Muneer A Mulla MS, ³Dr Haroonrasid MBBS,

⁴Dr Chandrashekhar D.M. MBBS,

Associate Professor, Senior Resident, Junior Resident, Junior Resident,

Department of surgery, Belgaum Institute of Medical Sciences

B. R. Ambedkar Road, Belgaum, Karnataka 590001, India

Abstract

Sepsis is defined as a clinical condition in which there is systemic inflammatory response syndrome co-exists with a clearly established focus of infection. Diabetes insipidus is a disease condition in which there is a large amount of free water excreted in urine. A 24 hour urine volume is more than 50 ml / kg / hour and the urinary osmolality is less than 300 mosmol/L and the urine has low specific gravity. The association of diabetes insipidus (DI) and sepsis is not uncommon but often it is overlooked.

Keywords - DIABETES INSIPIDUS, DI, SEPSIS.

I. INTRODUCTION

Diabetic insipidus is a clinical entity resulting from the deficiency of anti-diuretic hormone (ADH) action which results in passage of large amount of dilute urine with low specific gravity and low osmolality.

Diabetes insipidus in sepsis is commonly seen in the post – operative period after major operations such as laparotomies for peritonitis, major limb amputations for peripheral vascular diseases and other such septic conditions.

The attending surgeons often concentrate on managing septic focus than the effects of sepsis including diabetes insipidus.

We report a series of 4 cases of diabetes insipidus secondary to sepsis and its successful management with literature review.

CASE – 1

65 years old lady was admitted in May 2010 with severe abdominal pain, vomiting and fever from 5 days.

On examination the patient was an old lady thin, ill looking emaciated toxic and dehydrated. The patient was in hypotension (90/70) with tachycardia and tachypnoea.

The abdominal examination revealed the signs of peritonitis such as severe tenderness, guarding, rigidity and absent bowel sounds.

PERFORATIVE PERITONITIS was diagnosed and managed as such

Investigations:

Hb – 6.7 gm%, TLC – 16000/cmm, P – 85%, L – 15%

Bl. Gp – B +ve, Sr. Creat – 2.4mg%, RBS – 120mg%, HIV – Neg.

Chest X-ray – showed gas under the diaphragm.

Abdominal X-ray– showed haziness with ground glass appearance.

USG abdomen revealed collection in the pelvic paracolic gutters.

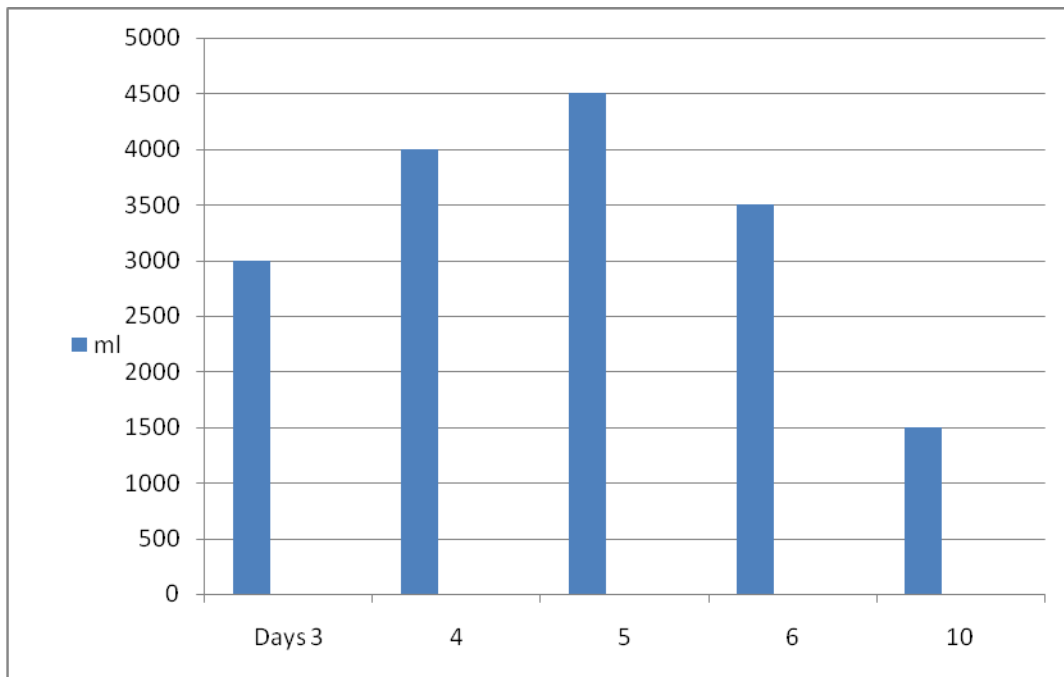
Aggressive resuscitation was done with IV fluids, broad spectrum antibiotics (taxim) and multiple blood transfusions.

The patient was stabilized and taken up for exploratory laparotomy under epidural anaesthesia. The findings were as follows: Recto –sigmoid perforation . Left tubo-ovarian mass, Bulky uterus. Pus in the lower abdomen more than 800ml.

Procedure done: Closure of perforation, left salphingo-oophorectomy and thorough saline wash and biopsy of the wall of perforation taken and the abdomen was closed with drains.

The patient was managed in SICU. The patient had stormy post-op period and recovery was slow. On the 3rd P.O.D. it was noticed that the urine output was 3000ml with transparent pale and clear urine. In the next 2-3 days the urine output was in large quantity. Detailed and through serum and urine was analysed. Diabetes insipidus secondary to sepsis noted.

Figure 1



Case 1: urine output

POD	3	4	5	610
Output	3000ml	4000ml	4500ml	3500ml 1500ml
Urine	output		Osmolality	sp.gravity	
Exam	3.0L/d		290Mosmol/L	1010	

Diabetes insipidus secondary to sepsis was noted and strict intake and output was monitored reducing IV fluids, not chasing urine output and the patient was encouraged to take orally and close monitoring of fluids, electrolyte balance ensured that diuresis was controlled and the urine output fell less than 2000ml by 7th day .
The patient was discharged in good condition on 12th P.O.D.

CASE II

A 35 years old man was admitted (Jan 2011) with acute pain abdomen, vomiting and abdominal distension since 2 days.
Past surgical history is very significant that he had duodinal ulcer perforation closure in 2005 and GJ & vagotomy in 2006 and since then the patient was on PPI medication on and off.
On examination the patient was a middle aged man ill, toxic, dehydrated, tachycardia, tachypnea with stable vital signs.
Abdominal examination showed all the signs of perforative peritonitis. Previous laparotomy scars

were noted. The patient was resuscitated for laparotomy.

Investigations:

Hb – 10.3 gm%, TLC – 12500/cmm, P – 80%, L– 15%, E-5% , Blood Group O +ve, BI.
Urea- 60mg% Sr. Creat – 2.4mg%, RBS – 140mg%, HIV – Neg.

Chest X-ray showed gas under the diaphragm.

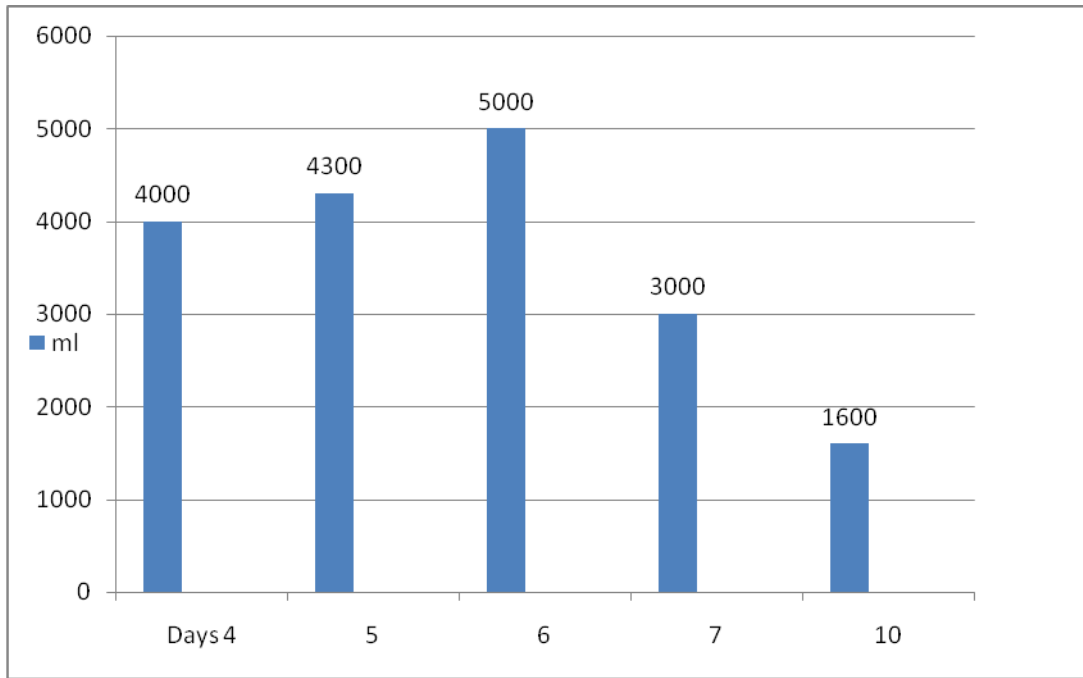
The patient had exploratory laparotomy and the perforation was located in the jejunum 2 cm from D-J junction. (Previous D-J was noted)

Closure of perforation with omental patch was done with thorough warm saline wash. The abdomen was closed in layers with drains.

The patient was in hypotension in the 1st 24 hours and was supported by dopamine drip.

Daily close monitoring revealed a large urine output on the 4th P.O.D. about 4000ml. the urine output was high in the next 4-5 days. Diabetes insipidus was suspected and managed by close monitoring of intake / output, correction of electrolyte imbalances, restriction of IV fluids and encouraging oral fluids was done. The patient was discharge on the 12th POD.

Figure 2



Case 2: urine output

POD	4	5	6	7.....	10
Output	4000ml/L	4300ml/L	5000ml/L	3000ml/L.....	1600ml
Urine output	Osmolality		sp.gravity		
Exam	4 L/d	300 Mosmol/L	1018		

CASE III

34 years old man was admitted in Feb 2011 with acute on chronic pain abdomen of 15 days duration. He was initially treated a private nursing home for 3-4 days. He had undergone operations for peptic ulcer disease twice, one in 2004 and another in 2005.

He is a known alcoholic and a chronic smoker. On admission the patient was a young man moderately built and nourished looked ill, sick and dehydrated with stable vital signs.

Abdominal examination revealed all the signs of peritonitis and previous scars were present.

The patient was resuscitated with IV fluids, antibiotics and Inj. Ranitidine. The patient was very unco-operative and pulled out NG tube and catheter which were re inserted later in OT. The patient was managed as having PERFORATIVE PERITONITIS.

Investigations

Hb – 12.3 gm%, TLC- 11500/cmm, P – 70% , L – 28%, E- 2% , Blood Group B +ve

Bl. Urea- 34mg% , Sr. Creat – 0.9mg%, Na- 139mg%, K – 5.2mg%, HIV – Neg.

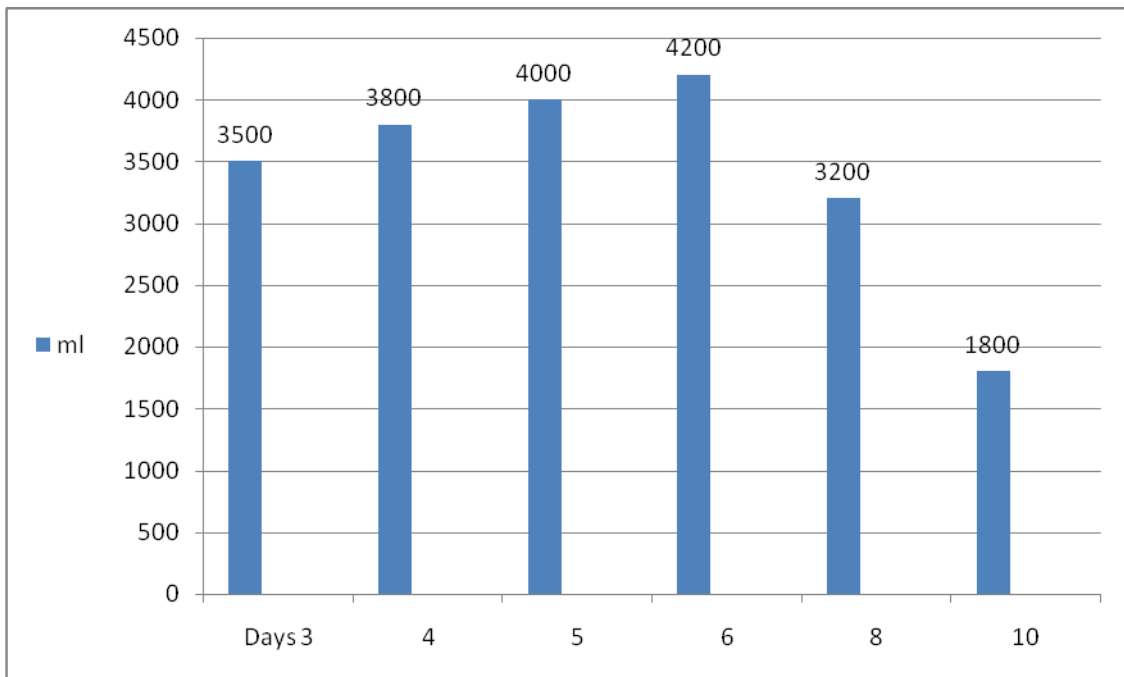
Liver functions and serum amylase – within normal limits.

Chest X-ray – showed gas under the diaphragm and USG abdomen showed Hepatomegaly with fatty changes and moderate ascites and minimal left sided pleural effusion.

The patient was taken up for exploratory laparotomy after resuscitation There was bile stained fluid in the peritoneal cavity, previous GJ was noted and there was perforation just adjacent to the GJ on the jejunal side. The perforation was closed with omental patch. The abdomen was closed after a thorough saline wash with drains. Post-operative period was stormy and the recovery was slow. ICD was introduced to drain pleural effusion on the left side. Chest infection needed vigorous chest physiotherapy and higher antibiotics.

Urine output was more than 3500ml to 4000ml for about 7-8 days. Diabetes insipidus secondary to sepsis was noted and managed.

Figure 3



Case 3: urine output

POD	3	4	5	6	8.....10
Output	3500ml	3800ml	4000ml	4200ml	3200ml.....1800ml
Urine	output		Osmolality		sp.gravity
Exam	3500ml/d		290 Mosmol/L		1010

The patient settled down in 7-8 days after careful management of intake / output, restriction of IV fluids, encouragement of oral fluids and correction of electrolyte imbalances. The patient was discharged on the 14 th POD.

CASE IV

30 years old man was admitted in Aug 2011 with severe pain abdomen, distension of abdomen and fever since 24 hours.

On examination the patient was a young man ill looking, febrile and dehydrated with stable vital signs. Abdominal examination revealed all the signs of perforative peritonitis.

The patient was resuscitated and hydrated.

Investigations:

Hb – 9 gm%, TLC-12,500/cmm, P – 80%, L – 18%, E- 2% ,
 RBS- 80mg% , Blood Group A+ve , Bl. Urea- 60mg%, Sr. Creat – 1.8mg%,
 Na- 132mg%, K– 5.1mg%, HIV – Neg.

Chest X-ray – showed gas under the diaphragm.

The patient was taken up for exploratory laparotomy under epidural anaesthesia. There was pus in the peritoneal cavity about 800 ml. Ileal perforation was noted about 20 cm from ileo-caecal junction which was closed after edge biopsy. The abdomen was closed after thorough saline wash with drains.

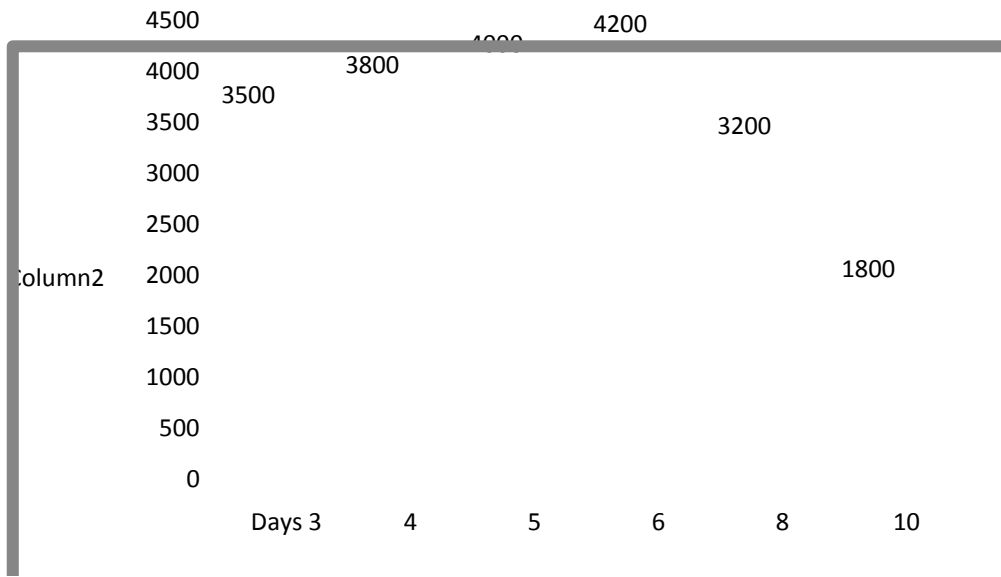
The post operative period was stormy and slow in recovery. The patient had severe pneumonia with pleural effusion which was managed with chest physiotherapy and higher antibiotics.

Histo-pathological report of the edge biopsy came as non specific ulcer.

The patient also had wound infection. The patient noted to have high urine output from 4th P.O.D. for about 6-7 days. Diabetes insipidus secondary to sepsis was noted and managed as such.

The patient recovered gradually and discharged on 16th P.O.D.

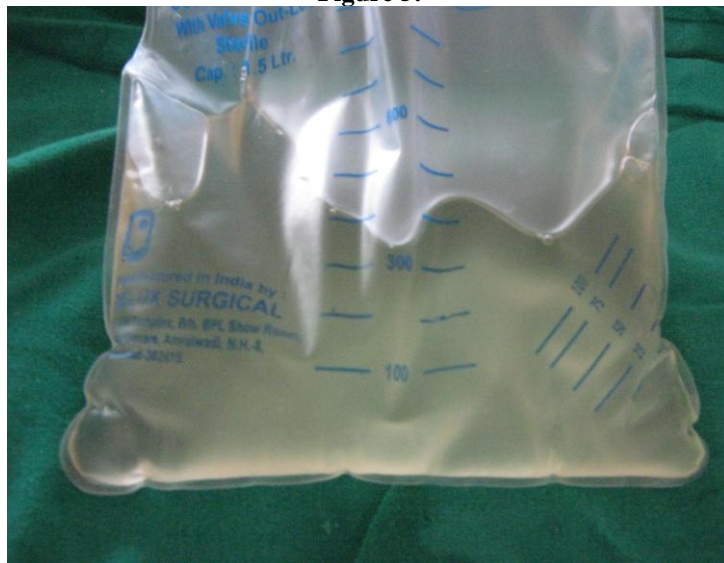Figure 4



Case 4 : urine output

POD	4	5	6	7.....10
Output	3350ml/L	5640ml/L	4000ml/L	3200ml/L.....2000ml
Urine output Exam	3.5 L/d	Osmolality 300 Mosmol/L	sp.gravity 1010	

Figure 5:



Clear watery urine

II. DISCUSSION

Diabetes insipidus is an uncommon clinical condition in which the kidneys are unable to conserve water. The amount of water conserved is controlled by ADH (anti diabetic hormone) also called as vasopressin.

ADH is hormone produced in hypothalamus and stored and released from the pituitary gland at the base of the brain. (1)

Diabetes insipidus is classified into

1. Central diabetes insipidus
2. Nephrogenic diabetes insipidus

3. Dispogenic diabetes insipidus
4. Gestational diabetes insipidus
5. Diabetes insipidus secondary to sepsis
6. Idiopathic when the exact cause is not identifiable.

Diabetes insipidus is defined as the passage of large volumes of urine more than 3 L / 24 hours of dilute urine whose osmolality is less than 300 mosm/kg.

Physiology of water balance

The normal range of plasma osmolality is between 275 and 295 mosm/kg. The ability of the

kidneys to modify the concentration of urinary solutes ranges between 50-1200 mOsm/kg. Healthy adults on a normal diet excrete 800-1200 mosm/kg of solute daily. Thus, to excrete 1000 mOsm of solute, the obligate urinary water excretion would be 1000 mOsm per 12000 mOsm/kg water, which translates into 0.8 kg (0.8 L) of water per day. This urine is maximally concentrated and appears dark yellow or orange in color. If this requirement for obligate water excretion is not met, solutes accumulate, leading to uremia.

Conversely the maximum volume of urine (secondary to limits imposed by renal dilutional capacity) is 20 L of water per day (1000 mosm/kg per 50 mosm/kg water). This maximally dilute urine is colorless.

The maintenance of water balance in healthy humans is principally accomplished through three robust, interrelated determinants: thirst, AVP, and the kidneys. In addition, recognition of a fourth factor, apelin, has emerged in recent years. Apelin is a bioactive peptide that is widely distributed throughout the body. In the brain, it is expressed in supraoptic and paraventricular nuclei, as well as in other sites, and has specific receptors located on vasopressinergic neurons. Apelin acts as a potent diuretic neuropeptide that inhibits ADH release.

AVP is the primary determinant of free water excretion in the body. Its main target is the kidney, where it acts by altering the water permeability of the cortical and medullary collecting tubules. Water is reabsorbed by osmotic equilibration with the hypertonic interstitium and returned to the systemic circulation. The actions of AVP are mediated through at least 2 receptors, V1 – Mediates vasoconstriction, enhancement of corticotrophin release, and renal prostaglandin synthesis. (2) V2 – Mediated the antidiuretic response.

Effects of reduced AVP or ADH

The vasoconstrictor effect of AVP is negligible in humans. No clinically significant defects in blood pressure regulation or cortisol secretion are apparent in patients with DI.

Diminished or absent ADH production can be the result of a defect in 1 or more sites in the neurohypophysis. These include the hypothalamic osmoreceptors, the supraoptic or paraventricular nuclei, and the supraopticohypophyseal tract.

Response to volume decrease

Ordinarily, a decrease in the extracellular fluid (ECF) volume elicits the following simultaneous responses:

Aldosterone secretion – To preserve sodium retention

Thirst – to raise water intake

AVP secretion – To increase water retention

Volume depletion activates baroreceptor mechanisms that exert similar effects on aldosterone, thirst and AVP whereas osmoreceptor-mediated mechanisms impact thirst and AVP secretion only.

Osmoreceptors for thirst are solute specific, responding preferentially to increased sodium levels in the ECF. Thus, elevated glucose levels in diabetes mellitus do not induce thirst; rather, the increased thirst in uncontrolled diabetes mellitus is secondary to volume depletion from osmotic diuresis.

Nephrogenic DI can also be caused by an acquired conditions such as Hypokalemia, Renal disease secondary to sickle cell anaemia, amyloidosis, Pregnancy can also cause DI which is usually transient, in some cases hypoglycemia can cause DI by osmotic diuresis.

Some drugs that are nephrotoxic which can cause DI are Amphotericin B, cidofovir, lithium, Demeclocycline, Ofloxacin and etc (3).

Hereditary, Nephrogenic DI is another entity which is relatively rare. There are mutations in the AVP receptor 2 gene on chromosome x q28 911). Defects in the gene are responsible for the unresponsive to ADH effects. Most of these are x – linked since it is seen in the males (4).

Gestational Diabetes Insipidus occurs only during pregnancy and it is due to an enzyme secreted by the placenta that alters the function of ADH in the mother.

Clinical features of Diabetes Insipidus are polyuria, polydipsia nocturia. The daily urine volume is constant, ranging from 3-4 litres per day. DI following trauma or surgery may exhibit three types of patterns transient, permanent or triphasic. Triphasic type is more seen in clinical conditions.

The first phase of triphasic pattern is polyuric usually lasts 4-5 days which is usually caused by inhibition ADH. There is increase in the urine volume and there is concomitant fall of urinary osmolality.

The second phase is diuretic phase that lasts for 5-6 days resulting on the stored hormones and urine osmolality raises.

The third phase can be permanent DI in which stores of ADH are exhausted and ADH is either absent or unable to produce the hormone (5).

Physical examination findings in DI vary with Severity and chronicity.

The findings may be entirely normal. Hydronephrosis, with pelvic fullness, flank pain and or tenderness may be present in the same region.

Management considerations

In a patient whose clinical presentation suggests diabetes Insipidus, detailed laboratory investigations are needed along with 24 hours urine output.

Urine is collected for 24 hours for both volume and specific gravity.

- Serum electrolytes and urine electrolytes are done along with serum glucose levels.
- Urinary and plasma osmolality is done simultaneously.
- Plasma ADH level to be done whenever possible.

These tests are done with the patients in maximally dehydrated as tolerable as at this period the ADH release is highest and urine is maximally concentrated.

Urinary specific gravity of 1.005 or less and urinary osmolality less than 200 mosm/kg are the hall mark of DI.

Random plasma osmolality is more than 287 mosm/ kg. Primary DI is suspected when there is large volume of dilute urine occurs and plasma osmolality is low- normal range.

Polyuria and an elevated plasma osmolality despite high basal level of ADH suggest nephrogenic DI. Water deprivation test also known as Miller Moses test. This is a semi quantitative test to ensure adequate dehydration and maximum stimulation of ADH for diagnosis usually performed in chronic forms of DI. Water intake is withheld, urinary osmolality and body weight are measured hourly. During the test when 2 sequential urinary osmolality vary less than 30 mosm/ kg or weight decreases by more than 3%, 5 Units of ADH is given sub-continuously. Final urine sample is taken 60 minutes later.

Healthy individuals have urinary osmolality 2-4 times greater than plasma osmolality. ADH in normal persons induces an increase less than 9% in urinary osmolality. Time required is about 4-8 hours.

In central and nephrogenic DI urinary osmolality is less than 300 mosm /kg after water deprivation. After ADH injection osmolality is risen more than 750 mosm/kg, in central DI and will not rise in nephrogenic DI. In primary polydipsia usually osmolality is 750 mosm/kg after water deprivation (6).

MRI-T, weighted images are helpful in the diagnosis of central DI. A hyper intense signal from the healthy posterior pituitary is seen in primary polydipsia. In central DI this signal is absent and also in most patients of nephrogenic DI (7).

The differential diagnosis of DI is often challenging but essential because treatment options vary. A detailed search was done of all articles pertaining to polyuria, polydipsia syndrome. Various factors were taken into consideration such as underlying diseases; clinical diagnostic and therapeutic modalities were studied. Diagnostic superiority of direct vasopressin assessment over indirect water deprivation test methods revealed limitations. It was concluded that newer available assay for co-peptin the 'C' terminus of the vasopressin precursor holds promise for a higher diagnostic specificity and simplification in the differential diagnosis of DI (8).

Pharmacological Support

Patient suffering from central type of DI, there is hormone deficiency hence physiological replacement is needed such as Desmopressin. It is a synthetic analogue of anti

diuretic Hormone (ADH) is given as a sub-cutaneous injection (9).

Desmopressin is in the clinical use for more than 30 years and its safety profile has been established. Desmopressin is available in various formulations such as intranasal spray since (1972), injectable since 1981, tablets since 1987 and also oral lyophilisate since 2005. The ADH property Desmopressin is used in various clinical conditions such as nocturnal enuresis, nocturia and Diabetic Insipidus. Intra nasal and oral formulations are well tolerated with minimum of side effects (10).

Management of central DI and transient DI of pregnancy is well tolerated and effective in using 1-deamino -8 D-arginine vasopressin (DDAVP). The use of DDAVP will prevent the increase complications of pregnancy such as preeclampsia and loss of fetus (11).

Argentine vasopressin is a key hormone in the human body. Clinical importance of AVP in maintaining fluid balance and vascular tone, estimation of mature AVP is difficult and prone to pre-analytical errors.

A 39 amino acid glycopeptides that comprises the 'C' terminal part of AVP pre-cursor was found to be stable and sensitive marker for AVP. Co-peptin estimation in various clinical conditions such as, DI monitoring for sepsis and cardio-vascular diseases (12).

III. SUMMARY AND CONCLUSIONS

Diabetes Insipidus is not an unknown clinical condition but occurs quite often in surgical patients. It requires high degree of suspicion whenever the surgical patient has large urine output in the post operative period.

We had 4 patients with diabetes insipidus.

Total Patients- 4

Female- 1

Male - 3

All patients had perforative peritonitis with sepsis.

All patients had undergone explorative laparotomy and closure of perforations of GI Tract

All the patients had large amount of urine in the post operative period.

All the patients were managed by close monitoring, correction of electrolyte imbalances and restriction of fluids and the most important factor is not to chase the urine output.

All the patients were discharged in good condition.

REFERENCES

- [1] Robinson AL, Verbalis JG, Posterior Pituitary In Kronberg HM, Melmed S, Polonsky KS, Larsen PR Eds/Williams Text book of endocrinology 12th Edition Philadelphia,Sander. Elsevier ;2011:chap 10.
- [2] Verkman AS, Aquaporins in clinical medicine. Annu Rev Med.2012;63:303-16 (Medline)
- [3] Stone KA, Lithium induced nephrogenic diabetes Insipidus. J Am Board Fam Pract. 1999 Jan-Feb;12(1):43-7

- [4] Babey M, Kopp P, Robertson GL. Familial forms of diabetes insipidus: clinical and molecular characteristics. *at Rev. Endocrinol.* 2011 Jul 5; 7(12): 701-14. (Medline).
- [5] Di Iorgi N, Napoli F, Allegeri AE, Ilivieri I, Bertelli E, Gallizia A, et al . Diabetes insipidus – Diagnosis and management. *Horm Res Paediatr.* 2012;77(2):69-84. (Medline).
- [6] Trepiccione F, Christensen BM. Lithium induced nephrogenic diabetes Insipidus: new clinical and experimental finding. *J Nephrol Nov-Dec 2010-23 Suppl 16:S43-8* (Medline)
- [7] Hadjizacharia P, Beale EO, Inaba K, et al. Acute diabetes Insipidus in severe head injury: a prospective study. *J. Am Coll Surg. At* 2008;207(4):477-84 (Medline)
- [8] Fenske W, Allolio B. Current Stale and future perspective in the diagnosis of Diabetic Insipidus : A clinical review *J. Clin Endocrinol Metab* 2012 Oct;97(10):3426-37. 242 Aug 1.
- [9] Hannon MJ, Sherlock M, Thompson CJ, Pituitary dysfunction following traumatic brain injury or sub-Arachnoid hemorrhage in “Endocrine management in the ICU” *Best pract Res Clin endocrinal Metab.* Oct-2011;25(5):783-98 (Medline)
- [10] Vande Walle J, Stockner M, Raes A, Norgaard JP. Desompressin 30 years in clinical use: a safety review. *Curr Drug saf.* Sep 2007 ;2(3):232-8
- [11] Ananthkrishana S. Diabetes insipidus is pregnancy: etiology evaluation and management. *Endo pract* 2009 May- Jun; 15(4):377-82
- [12] n.margenthaler@brahms.de PMD18291667 (pubmed for Medline)