

Unprecedented PR Interval Prolongation in a Rheumatic Fever Recurrence

Dr. Amit Chaudhary M.D.¹, Dr. Laxmi H. Shetty¹ M.D., Dr. Amjad Ali¹ M.D.,
Prof. Cholenahally Nanjappa Manjunath M.D.,D.M²

¹Senior Resident in cardiology department, Sri Jayadeva Institute of Cardiovascular Sciences and Research, India

²Professor of cardiology department, Sri Jayadeva Institute of Cardiovascular Sciences and Research, India

Abstract

Abnormalities of conduction forms a minor diagnostic criterion in modified Jones criteria. Our patient was diagnosed as rheumatic fever on basis of clinical evidence and positive ASLO. Infective endocarditis was ruled out by negative blood cultures and echocardiogram. During hospital stay she had transient extraordinary prolonged PR interval which recovered uneventfully. 24 hour holter did not reveal any atrioventricular conduction abnormality. To best of our knowledge such isolated cases of marked PR prolongation has never been reported.

Keywords -rheumatic fever, PR interval, atrioventricular conduction

I. INTRODUCTION

A number of reports of PR prolongation in rheumatic fever studied by various methods have been published (Cohn and Swift, 1924; Keith, 1938; Taran, 1946; Blackman and Hamilton, 1948; Sokolow, 1948; Mirowski, Rosenstein, and Markowitz, 1964). This article features unexpected PR interval prolongation related to rheumatic fever recurrence.

II. CASE REPORT

18 year old female known case of Rheumatic heart disease presented with history of dyspnoea on exertion, fever and arthralgia. She was noncompliant with her penicillin prophylaxis. On examination her blood pressure was 94/70 mm Hg, pulse 76 /min. Cardiac examination revealed prominent first heart sound and loud P₂ and long grade IV/VI middiastolic murmur with opening snap. Interestingly she developed presyncope in hospital associated with bradycardia. ECG at that time revealed prolonged PR interval (around 1 sec) with bradycardia, [Fig 1A]. Chest radiograph revealed borderline cardiomegaly, straightening of left heart border, widening of carinal angle, left atrium enlargement and pulmonary venous hypertension, all suggestive of rheumatic mitral stenosis. Rhythm strip did not reveal AV dissociation. Patient soon reverted to sinus rhythm, [Fig 1B]. 24 hour holter revealed sinus rhythm with 1:1 atrioventricular conduction.

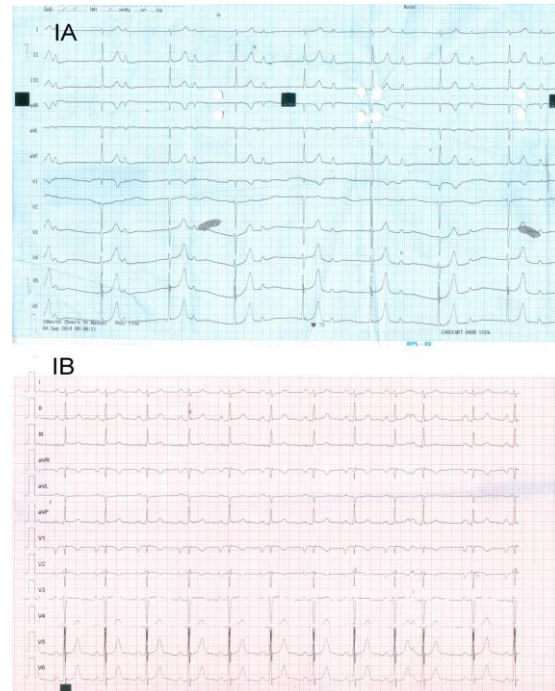


Figure 1A(above) electrocardiogram showing marked PR interval prolongation, right axis deviation and right atrium enlargement, Figure 1B(below, after spontaneous recovery) electrocardiogram showing normal sinus rhythm and left atrium enlargement

On further evaluation she had evidence of rheumatic activity in form of increased leukocyte counts, positive ASLO and raised ESR. Three blood cultures from separate venipuncture sites were negative. Patient developed presyncope due to rheumatic activity with PR prolongation and bradycardia. It is unusual to have such massive PR prolongation with rheumatic activity at this stage.

Echocardiography revealed Rheumatic heart disease-severe mitral stenosis, submitral fusion and bilateral fused commissures with Wilkins score of 8,

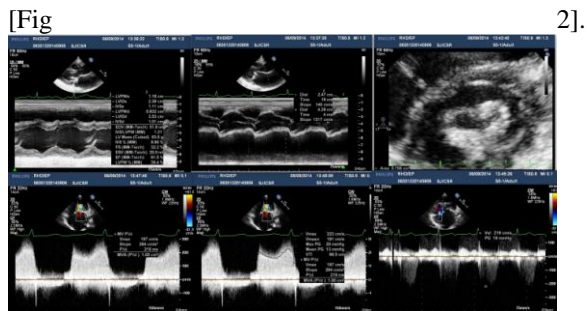


Figure 2 echocardiogram showing severe mitral stenosis , submitral fusion with Wilkins score of 8.

She was treated with intramuscular benzathine penicillin and aspirin and started on rheumatic fever prophylaxis. Patient successfully underwent percutaneous balloon mitral commissurotomy in follow up. Her mitral valve area improved to 2.2 cm². She is doing well with normal atrioventricular conduction.

III. DISCUSSION

In active rheumatic fever each segment of electrocardiogram may be altered and rhythm may also be disturbed. By far, the most common change is increase in PR interval. In the observations of different investigators, this change has been noted in varying proportions, from the 93.8 per cent of Rothschild,[1] Sachs and Libman and 84 per cent of Cohn and Swift,[2] to the 5 per cent in cases of Filberbaum, Griffith, Solley and Leake, [3]. Discrepancies such as these are due to various factors. The electrocardiographic changes in rheumatic fever are fleeting, and hence, the more frequently the tracings are taken, the greater likelihood of detecting abnormalities. The degree of AV delay as demonstrated by the electrocardiogram may vary from findings within normal, through various stages, upto complete dissociation. But PR prolongation without atrioventricular dissociation, of such magnitude has never been reported.

Cohn and Swift have demonstrated that, in the normal individual, prolongation of PR interval can occur, probably as a result of vagal influence. However, these changes do not exceed 0.02 seconds. An increase of 0.04 seconds then would be indicative of a pathologic process or function. Ziegler[4] has noted that the PR interval is prolonged in 2% of normal children. Because the PR interval varies with age and heart rate, Mirowski et al,[5] devised the PR index to provide a standard by which the duration of the PR interval of a subject may be judged. A value greater than 1.0 is considered evidence of delay in atrioventricular (AV) conduction. In our case, PR prolongation is so obvious that PR index calculation is not needed.

IV. CONCLUSION

In 1965, the revised Jones criteria,[6] listed prolongation of the PR interval as one of the minor criteria used in establishing the diagnosis of rheumatic fever. Other conduction abnormalities may be observed. Clarke and Keith,[7] detected AV conduction abnormalities in 84%. To best of our knowledge, there are no reports of such noteworthy prolonged PR interval in literature. These findings make this case unique.

Conflict of Interest: All authors have none to declare

REFERENCES

- [1] Rothschild, M. A., Sachs, B., and Libman, E. Disturbances of the cardiac mechanism in subacute bacterial endocarditis and rheumatic fever, *Am. Heart J.* 1927 April;2:356.
- [2] Cohn, A. E., and Swift, H. F. Electrocardiographic evidence of myocardial involvement in rheumatic fever, *J. Exper. Med.* 1924 Jan;39:1.
- [3] Filberbaum, M. B., Griffith, G. C., Solley, R. F., and Leake, Wm H. Electrocardiographic abnormalities in 6,000 cases in rheumatic fever, *California and Western Med.* 1946 June;64:340
- [4] Ziegler, D.K. Multiple sclerosis and rheumatic fever: related diseases. *Dis. nerv. Syst.* 1959;20:221
- [5] Mirowski M, Rosenstein Bj, Markowitz M. A comparison of atrio-ventricular conduction in normal children and in patients with rheumatic fever, glomerulonephritis, and acute febrile illnesses. a quantitative study with determination of the P-R index. *Pediatrics.* 1964 Mar;33:334-340
- [6] Jones Criteria (Revised) for Guidance in the Diagnosis of Rheumatic Fever, *Circulation.* 1965;32:664-668, doi:10.1161/01.CIR.32.4.664
- [7] Clarke M., Keith J. D. Atrioventricular conduction in acute rheumatic fever. *Br Heart J* 1972;34:5 472-479doi:10.1136/hrt.34.5.472.