

Incidental Asymptomatic Meckel's Diverticulum : A Therapeutic Dilemma

Dhruv Nayan Kundra¹, Rohit Agarwal¹, Anju Gupta¹, Surendra Vashishth¹

¹ Department of Surgery, Acharya Shree Bhikshu Government Hospital, Moti Nagar, New Delhi 110015, India

Abstract :

Incidental discovery of Meckel's diverticulum during surgery presents as a dilemma as to whether it should be removed or not. The risks from complications from Meckel's diverticulum have to be weighed against those associated with an incidental diverticulectomy. We present the case of a 40 year male patient who was posted for an interval appendicectomy. Intraoperatively Meckel's diverticulum was found and a wedge resection was done along with appendicectomy.

Keywords - Incidental diverticulectomy, interval appendicectomy, Meckel's diverticulum

I. INTRODUCTION

Meckel's diverticulum's incidence in the general population has been estimated to be about 2% [1]. However, autopsy and retrospective studies give a range from 0.14-4.5% [2, 3]. As it causes complications more frequently in males, hence it is more commonly diagnosed in males [4-6]. Incidental discovery of Meckel's diverticulum during surgery for a different cause leads to a situation where decision has to be made by the surgeon considering the risks and benefits of removing the Meckel's diverticulum.

A Meckel's diverticulum has 4-6% lifetime risk of developing complications like hemorrhage, obstruction, intussusceptions, diverticulitis and perforation [7]. Whereas an incidence of up to 7% has been reported of early and late postoperative complications resulting from the diverticulectomy like wound infection, prolonged ileus, anastomotic leak and adhesive small bowel obstruction [6].

II. CASE REPORT

A 40 years old male patient who was a diagnosed case of recurrent appendicitis was posted for an elective open appendicectomy. Abdomen was opened by Mc Burney's incision. Appendix was located and it was not markedly inflamed, oedematous or adherent to surrounding structures (Fig 1). On examination of rest of bowel a diverticulum was located around 70 cms from caecum. It was 10 cms in length with wide circumference and wide base (Fig 2). On palpation mucosa appeared thickened. After examining rest of bowel a decision was taken to carry out both appendicectomy and wedge resection of Meckel's diverticulum. After the procedure abdomen was closed in layers, no drain was used. Patient was started on oral feed from next day and sutures were removed on seventh day. Histopathology report did not indicate any malignant changes in Meckel's diverticulum mucosa.

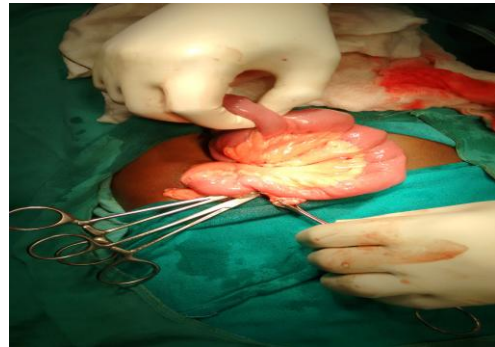


Fig. 1: Intraoperative view of Meckel's diverticulum and Vermiform appendix

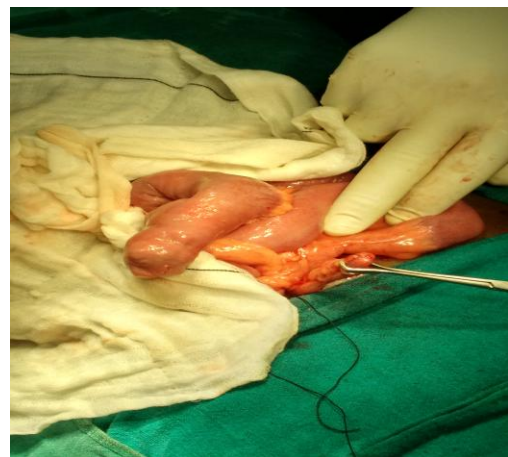

Fig. 2: Meckel's diverticulum (above 10 cms and wider circumference) and Vermiform appendix (below 7cms)

III. DISCUSSION

Meckel's diverticulum is a true diverticulum, with all layers of the bowel wall. It has equal incidence in both males & females, but the complications are frequent in males [6]. The vast majority of Meckel's Diverticula are clinically silent (symptomatic in 5-6% cases). Symptomatic lesions usually present before two years of age. It is often referred to by the rule of 2's; 2% of the population, within 2 feet of the ileocecal valve, 2 inches in length, 2 types of heterotopic mucosa, and presentation before the age of two [8].

It is a common saying amongst surgeons that "Meckel's Diverticulum is frequently suspected, often looked for and seldom found".

The management of asymptomatic Meckel's Diverticula found during laparotomy is controversial. The incidence of complications from prophylactic resection

is approximately 1-6%. This is in comparison to the lifelong potential complication rate of 5-7% in all individuals with a Meckel's Diverticulum, according to various studies. It is recommended by some that the risk to benefit ratio favors the resection of all Meckel's Diverticula when found incidentally [4,6]. Prophylactic removal is however contraindicated in patients with omphalocele[8].

IV. CONCLUSION

In absence of a universally accepted protocol for incidentally encountered asymptomatic Meckel's Diverticulum decision for diverticulectomy has to be taken by surgeon on the basis of individual case. Patient's history, size and appearance of Meckel's Diverticulum as well as palpation findings hinting towards thickened or abnormal mucosa may help making the decision for diverticulectomy.

ACKNOWLEDGEMENTS

I would like to acknowledge the help of my colleagues Dr Nitin Aggarwal & Dr Pankaj Sareen for their contribution in preparing this case report.

REFERENCES

- [1] Standing S, ed. Gray's Anatomy. The anatomical basis of clinical practice. 39th Ed., London, Elsevier Churchill Livingstone. 2005; 1167.
- [2] Lütke FE, Mende V, Köhler H, Lepsien G. Incidence and frequency of complications and management of Meckel's diverticulum. Surg Gynecol Obstet. 1989; 169: 537–542.
- [3] DiGiacomo JC, Cottone FJ. Surgical treatment of Meckel's diverticulum. South Med J. 1993; 86: 671–675.
- [4] Arnold JF, Pellicane JV. Meckel's diverticulum: a ten year experience. Am Surg. 1997; 63: 354–355.
- [5] Mackey WC, Dineen P. A fifty year experience with Meckel's diverticulum. Surg Gynecol Obstet. 1983; 156: 56–64.
- [6] Cullen JJ, Kelly KA, Moir CR, Hodge DO, Zinsmeister AR, Melton LJ 3rd. Surgical management of Meckel's diverticulum. An epidemiologic, population-based study. Ann Surg. 1994; 220; 564–569.
- [7] Pollack Raymond. Adjunctive Procedure in Intestinal Surgery. Mastery of Surgery. Fifth edition. 2007:1392-1393.
- [8] Anthony Stallion, Jerry M Shuck. Meckel's diverticulum. Surgical Treatment: Evidence-Based and Problem-Oriented. 2001:392-393