

# Laparoscopic Management of CBD Stones with Primary Closure over Endobiliary Stent

Iqbal S. Mir<sup>1</sup>, Farooq A. Reshi<sup>2</sup>, Imtiyaz Ali<sup>3</sup>, Abdul R. Ganae, Shoukat A Kadla, Kulwant S. Bhau, Aftab Akbar, Mohd Yaqoob, Mansoor U. Haq, Sidiqa Banoo

<sup>1</sup>Associate Professor, Department of General Surgery, Government Medical College Srinagar, J&k, India.

<sup>2</sup>Professor, Department of General Surgery, Government Medical College Srinagar, J&k, India.

<sup>3</sup>Postgraduate Student, Department of General Surgery, Government Medical College Srinagar, J&k, India.

## Abstract

**Background:** The concomitant laparoscopic Common Bile Duct exploration with clearance (LCBDE) of CBD stones during cholecystectomy has demonstrated many advantages when compared with other surgical techniques. We study the outcomes of primary CBD closure over endobiliary stent in patients who underwent laparoscopic CBD exploration for CBD stones.

**Patients and method:** we studied retrospectively a series of 38 patients with majority of them being females (26), who underwent LCBDE for CBD stones from May 2009 till June 2017 in our Hospital. Results: No mortality was reported in our study. The CBD clearance rate with laparoscopy was around 89 % in this study with short hospital stay and fewer complications. Patients with residual CBD stones were later removed Endoscopically in the postoperative period without any difficulty or increasing the morbidity.

**Conclusion:** Indeed, laparoscopic CBD exploration is a feasible, effective and safe method. With anterograde stenting during this procedure the morbidity associated with T-Tube is avoided with the same benefit of Biliary Decompression. It should be given preference against T-tube.

**Keywords -** Endobiliary stent, choledocholithiasis, choledochotomy, common bile duct, endoscopic retrograde cholangiopancreatography, nephroscope.

## I. INTRODUCTION

Prior to the introduction of laparoscopic cholecystectomy, choledocholithiasis was documented in approximately 9-16% of those patients who presented for open cholecystectomy.<sup>[1]</sup> The incidence of common bile duct (CBD) stones remains around 10% today.<sup>[3]</sup> The incidence increases with age to over 80% in those who are over 90 years of age.<sup>[4]</sup> Definitive treatment of these patients includes cholecystectomy and clearance of the ductal system. In 1890, nearly eight years after Langenbuch performed the first “open” cholecystectomy, Courvoisier showed that the CBD could be cleared at the time of cholecystectomy.<sup>[5]</sup> Around one hundred years later, laparoscopic cholecystectomy (LC) became the standard of care for treatment of symptomatic

gallbladder disease. Surgical techniques have advanced tremendously in the past decade, however, the management of concomitant gallbladder and common bile duct (CBD) stones still remains controversial and a matter of debate.

The concomitant laparoscopic CBD exploration with clearance of CBD stones during cholecystectomy has demonstrated many advantages when compared with other surgical techniques.<sup>[6]</sup> Laparoscopic CBD exploration has been found to be successful in 70% to greater than 90% of patients having CBD stones.<sup>[7]</sup> Laparoscopic CBD exploration, however, requires fine laparoscopic surgical skills with the availability of proper equipment and facilities. The laparoscopic clearance of CBD stones can be achieved via two approaches, i.e., transcystic and choledochotomy. Both of these methods are useful and have precise indications. Further, in cases where patients need biliary decompression after stone clearance, a T-tube or a stent can be placed. It should be noted that a T-tube placed via a choledochotomy has been associated with higher morbidity rates.<sup>[8]</sup> In this regard, placement of a stent via cystic duct (transcystic) or choledochotomy has been found to be a safe and valuable alternative to avoid T-tube related complications.<sup>[9]</sup>

## II. PATIENTS AND METHODS

We present our experience of a retrospective case series conducted in our institution analysing the outcomes of primary CBD closure over endobiliary stent in patients who underwent laparoscopic CBD exploration for CBD stones by a single surgical team. All laparoscopic CBD explorations were done via choledochotomy. All patients underwent laparoscopic cholecystectomy in the same sitting. This study was conducted during May 2009 and June 2017.

The series included a total of 38 patients, of which 26 were females and 12 were males. The majority of patients belonged to the age group of 25–75 years. All patients had confirmed choledocholithiasis by preoperative imaging studies. MRCP was done in a few selected patients due to financial constraints. Patients with cholangitis had undergone emergency ERCP first to decompress the

biliary system and relieve the hepatobiliary sepsis. Upon resolution of the infection, these patients were taken for laparoscopic cholecystectomy with laparoscopic CBDE if the initial ERCP had not cleared the stones or the conventional two-stage procedure.

After proper preoperative evaluation and anesthetic clearance, patients were taken up for laparoscopic CBD exploration under general anaesthesia. With the patient in supine position, the American technique of laparoscopic cholecystectomy was used. A standard 4- port approach was used. On a few occasions, an additional 5 mm port was introduced midway between the right hypochondrial and infraumbilical ports so as to aid in the lavage and suction of CBD. A standard laparoscopic cholecystectomy was done in all cases. Titanium clips were used to clip the cystic artery and cystic duct after meticulous dissection of the Calot's triangle. After placing the sentinel clip on the cystic duct, Gallbladder was not lifted off the bed so as to aid in traction during the procedure. Skeltonization of CBD was done up and below with careful dissection. Kocherization of duodenum was done up to the lateral border of inferior vena cava so as to straighten out the CBD whenever required. The position of CBD was confirmed by needle aspiration. A longitudinal incision of 1–1.5 cm or equal to the size of the largest stone was made on the CBD. Stay sutures were not given [Figures 1 and 2]. In most of the patients, the stones were extruded via the choledochotomy by gentle milking with instruments. Stones were also retrieved by Dormia basket [Figures 3 and 4]. An 8 mm Nephroscope introduced through the epigastric port was used to irrigate the CBD distally with normal saline so as to help in the extrusion of stones. In a few cases, the stones were retrieved with the help of curved Desjardines forceps, and introduced directly through the epigastric wound after removal of epigastric port. This was done to clear the distal CBD.

In some cases, where the stone was impacted high up or far lower down, or the stone was large and impacted and could not be retrieved easily, a 4 mm rigid ureteroscope was introduced through the additional port midway between the right hypochondrial and infraumbilical ports for distal stones and through the infraumbilical port for upper stones. Stones were fragmented by means of contact lithotripsy using pneumatic lithotripter. CBD was cleared of remaining small segments by forceful saline lavage. Clearance of CBD was confirmed by directly visualizing the lumen of CBD with help of 8 mm Nephroscope introduced through the epigastric port. For stent placement, a guide wire (0.035 inch in diameter) was passed through the side channel of Nephroscope, over which a 7 or 10 French biliary stent was guided into the CBD up to the duodenum

across the papilla [Figure 5]. The choledochotomy was then closed by interrupted 3- 0 vicryl sutures with the intracorporeal knot-suturing technique [figure 6]. The gallbladder was now lifted off the liver bed and delivered via the epigastric port. An additional tube drain was put in the subhepatic region. Haemostasis was secured, pneumoperitoneum was deflated, and port sites were closed.

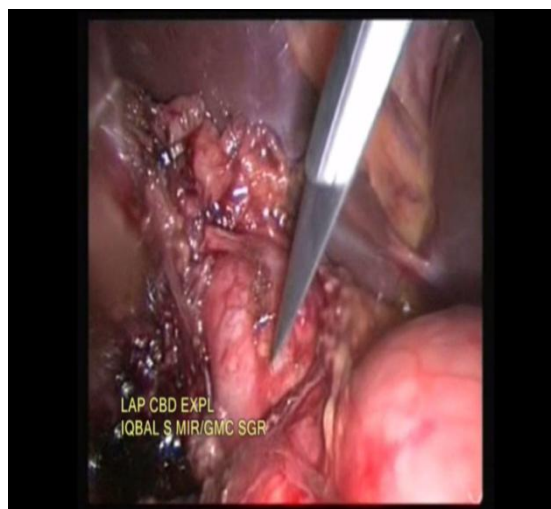

Fig 1 Choledochotomy

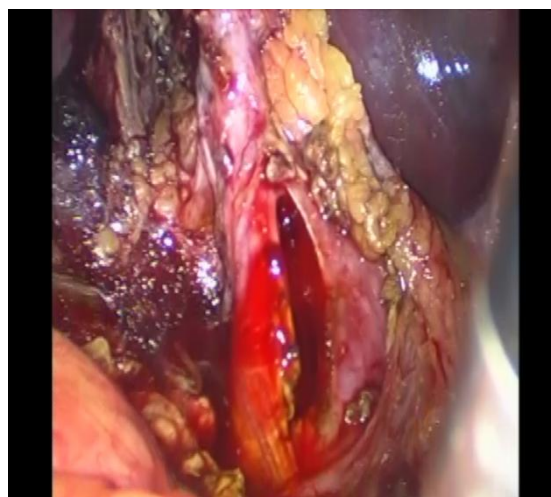


Fig 2 Choledochotomy

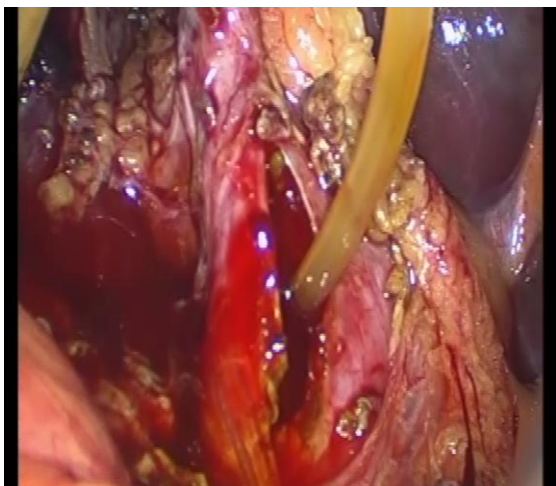


Fig 3 Removal of worm from CBD

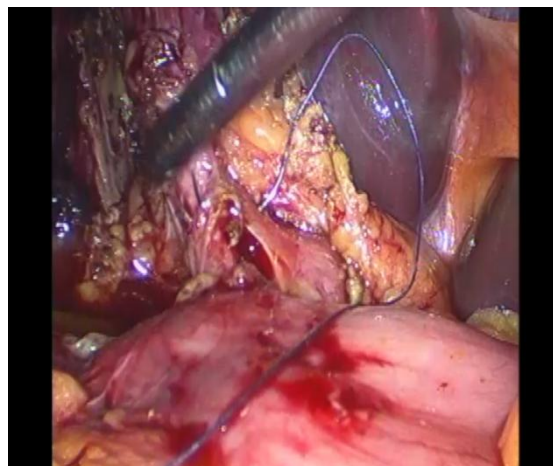


Fig 6: Closing CBD over endobiliary stent

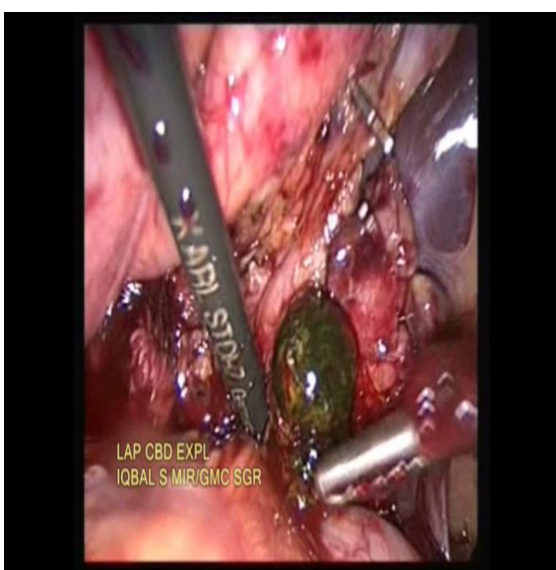


Fig 4 Removal of stone from CBD

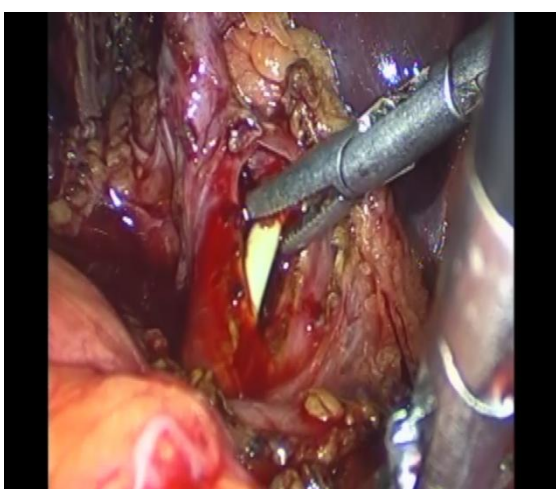


Fig 5: Endobiliary stent placing in CBD

### III. RESULTS

A total of 38 patients, with age ranging from 25 to 75 underwent laparoscopic CBDE for choledocholithiasis from May 2009 to June 2017. The majority of patients were female (68.42%). Of all the 38 patients, 37 underwent LCBDE. We had to convert the laparoscopic procedure to conventional open CBD Exploration in One patient due to severe adhesions present in the Calot's triangle and the duct couldn't be visualized properly. . The most common presentation in these patients was right upper quadrant or epigastric pain (19 patients), followed by jaundice or icterus (12 patients) and 7 patients had a history of prior hospitalization due to acute pain in the abdomen for (acute cholecystitis, acute cholangitis, acute pancreatitis), for which they were managed conservatively. 8 patients among these were those who had undergone ERCP beforehand. Despite documented clearance of stone in these 2 patients, stones were still found in the CBD on imaging investigations. This illustrates the problem of continual passage of stones from the gallbladder in the interval between ERCP and the subsequent cholecystectomy. Rest of the five patients were referred from Gastroenterology in view of failed ERCP for one or another reason.

The successful clearance of CBD was achieved in 34 patients (89.47%). Four patients (10.52%) who had residual disease were rendered free of the same by postoperative ERCP. The operative time ranges from 90-150 minutes with a mean of 110 minutes. After an initial 24 hours of NPO in the postoperative period, orals were started on the first operative day after the conformation of Bowel sounds clinically. The mean hospital stay was 2-3 days. All the patients had an intra-abdominal drain and was removed as the patients started oral diet and the drain output was <30 ml/day. Thirty five (92.10%) patients had their tube drains removed on the 3<sup>rd</sup> or 4<sup>th</sup> postoperative day. Three (7.89%) patients who had persistent drainage of more than 50 ml/day had their drain removed on the 7<sup>th</sup>

postoperative day. All the patients were followed weekly for the first two weeks in the postoperative period. All the stents were removed endoscopically at 4 weeks. All the patients were then put on follow up every 3 monthly in the first year and yearly thereafter till 2017.

**Table 1**  
**Characteristic of the 32 patients who underwent LCBDE**

<b>Median age(y)</b>	<b>55( range 27-75)</b>
<b>Males</b>	26(68.42%)
<b>females</b>	12(31.57%)

**Table 2**

<b>Presentation</b>	<b>Patients (%)</b>
<b>Pain upper abdomen</b>	19(50%)
<b>Jaundice</b>	12(31.57%)
<b>Others</b>	7(18.42%)

**Table 3**

<b>RESULTS</b>	
<b>parameters</b>	LCBDE with Stenting
<b>Mean operative time</b>	90-150 minutes
<b>Mean hospital stay</b>	2-3 days
<b>Mean time for abdominal tube removal</b>	2 days
<b>Conversion to open</b>	1
<b>mortality</b>	none
<b>Patients satisfaction</b>	Good

**Table 4**

<b>Complications</b>	
<b>Biliary leak</b>	None
<b>Localised Abscess</b>	None
<b>Transient cholangitis</b>	6
<b>Mild pancreatitis</b>	6
<b>Displacement</b>	None
<b>Port site infection</b>	none

#### IV. DISCUSSION

Earlierly it was the norm to do ERCP for patients diagnosed with CBD stones in the early laparoscopic era and was the preferred treatment for most surgeons. [10-12] However, this approach presented several disadvantages. Firstly, ES is successful in >90% of the patients but it is highly dependent on the availability of an experienced endoscopist to achieve such a high success rate. [13] Secondly, there are no selective criteria that can accurately predict the presence of CBD stone. [14] Taking into account all the positive predictors (history, clinical, biochemical, and sonography) for CBD stone, in most of the series reported in the literature, positive ERCP occurs in only up to 30-

35% of the cases. [15] On the other hand if we do routine IOC, we detect the stone in about 10% of cases and on selective IOC, CBD stones can be detected in about 25% of the cases. [16]

Finally, the risk of potential complications of ERCP and ES should be considered. Although the complication rate is decreasing with increasing experience, pancreatitis continues to be a problem in most of the reported series, with an incidence of morbidity up to 7% and mortality of 0.2-2.3%. [17] The Sphincter of Oddi (SOD) provides a barrier that prevents duodeno-biliary reflux and this function is permanently lost after sphincterotomy. [18] ES increases duodenal reflux and a higher rate of bacteribilia (60%) with the increasing rate of recurrent biliary stone formation. [19]

With the improvement in the technology and expertise of laparoscopic surgery, LCBDE has become an effective, feasible method and has been found to have good results. [20,21] LCBDE has made it possible to avoid the disadvantages of both a two- staged procedure (preoperative ERCP plus laparoscopic cholecystectomy) and the open CBD exploration. With the advent of laparoscopic techniques and instrumentation, recent studies have demonstrated the advantages of laparoscopic CBD exploration as a single stage procedure, with results equivalent to those of ERCP with shorter hospital stay. [22] The risks of sphincterotomy (during ERCP), such as cholangitis and pancreatitis, are significantly reduced because of the preservation of functions of sphincter of Oddi, following a laparoscopic CBD exploration. Laparoscopic CBD exploration has also been shown to be cost- effective. [23]

As CBD Exploration with T-Tube drain adds up to increase morbidity in terms of discomfort, longer hospital stays, increase chance of infection, fear to displacement. [24] Lange et al first reported laparoscopic CBD primary closure with antegrade stent. [25] Recently, many studies have shown feasibility and potential advantages of antegrade stent which include decompression of CBD postoperatively, facilitation of ERCP cannulation postoperatively and early return to full activity. [26] Mir IS and Etal [27] has also advocated endobiliary stent over T-tube in there comparative study.

The success rate in performing laparoscopic CBDE in our series was 89.5% and is comparable to those reported in the literature. [20, 21] In the remaining patients (10.5%), the CBD were cleared by postoperative ERCP successfully. The mean hospital stay in our series was 2-3 days which was comparable with other studies in the literature. [21]

All the stents were removed successfully after four weeks of surgery endoscopically. There was no mortality in our study and the patient satisfaction

was good. The only drawback with stenting in LCBDE is the requirement of postoperative endoscopic removal of the endobiliary stent. However, if we compare the morbidity associated with the T-Tube, definitely antegrade stenting is a better option of biliary decompression after LCBDE in terms of fewer complications, early recovery and less discomfort for the patient.

## V. CONCLUSION

Indeed, laparoscopic CBD exploration is a feasible, effective and safe method. With antegrade stenting during this procedure the morbidity associated with T-Tube is avoided with the same benefit of Biliary Decompression. It should be given preference against T-tube.

Financial Support And Sponsorship Nil.

### Conflict Of Interest

There are no conflicts of interest

## REFERENCES

- [1] Nahrwold D. The biliary system. In: Sabiston X, ed. *Textbook of surgery*. Philadelphia: WE Saunders, 1986.
- [2] Way LW, Admirand WJ, Dunphy JE: Management of choledocholithiasis. *Ann Surg*. 1972; 176: 347-359.
- [3] Petelin JB. Laparoscopic common bile duct exploration: Lessons learned from > 12 years experience. *Surg Endosc*. 2003, Nov; 17(11): 1705-15.
- [4] Shojaiefard A, Esmailzadeh, Ghafouri A, Mehrabi A. Various techniques for surgical treatment of common bile duct stones: A meta review. *Gastroenterol Res Pract* 2009;840208.
- [5] Beal J. Historical perspective of gallstone disease. *Surg Gynecol Obstet*.1984; 158: 181-9.
- [6] Decker G, Borie F, Millat B, Berthou JC, Deleuze A, Drouard F, et al. One hundred laparoscopic choledochotomies with primary closure of common bile duct. *Surg Endosc* 2003;17:12-8.
- [7] Hunter JG. Laparoscopic transcystic common bile duct exploration. *Am J Surg* 1992;163:53-8.
- [8] Cuschieri A, Lezoche E, Morino M, Croce E, Lacy A, Toouli J, et al. Multicenter prospective randomized trial comparing two stage vs single stage management of patients with gallstone disease and ductal calculi. *Surg Endosc* 1999;13:952-7.
- [9] Isla AM, Griniatsos J, Karvounis E, Arbuckle JD. Advantages of laparoscopic stented choledochoraphy over T-tube placement. *Br J Surg* 2004;91:862-6.
- [10] Hauer-Jensen M, Kåresen R, Nygaard K, et al. Predictive ability of choledocholithiasis indicators. A prospective evaluation. *Ann Surg*. 1985;202:64-68.
- [11] Neuhaus H, Feussner H, Ungeheuer A, Hoffmann W, Siewert JR, Classen M. Prospective evaluation of the use of endoscopic retrograde cholangiography prior to laparoscopic cholecystectomy. *Endoscopy*. 1992;24(9):745-749.
- [12] Liu TH, Consorti ET, Kawashima A, et al. Patient evaluation and management with selective use of magnetic resonance cholangiography and endoscopic retrograde cholangiopancreatography before laparoscopic cholecystectomy. *Ann Surg*. 2001;234(1):33-40.
- [13] Freeman ML, Nelson DB, Sherman S, Haber GB, Herman ME, Dorsher PJ, et al. Complication of endoscopic biliary sphincterotomy. *N Engl J Med* 1996;335:909-18.
- [14] Decker G, Borie F, Millat B, Berthou JC, Deleuze A, Drouard F, et al. One hundred laparoscopic choledochotomies with primary closure of the CBD. *Surg Endo* 2003;17:12-8.
- [15] Petelin JB. Laparoscopic Common Bile Duct exploration. *Surg Endo* 2003;17:1705-15.
- [16] Berci G, Morgensern L. Laparoscopic management of CBD stones: A multi-institutional SAGES study. *Surg Endo* 1994;8:1168-75.
- [17] Tranter Se, Thompson MH. Comparison of endoscopic sphincterotomy and laparoscopic exploration of CBD. *BJS* 2002;89:1495-504.
- [18] Bergman JJGHM, Van Berkel AM, Groen AK, Schoeman MN, Offerhaus J, Tytgat GN, et al. Biliary manometry, bacterial characteristics, bile composition and histologic changes fifteen to seventeen yr after ES. *Gastrointest Endosc* 1997;45:400-5.
- [19] Sand J, Airo I, Hiltrunen KM, et al. Changes in biliary bacteria after endoscopic cholangiography and sphincterotomy. *Am Surg* 1992;58:324-8.
- [20] Berci G, Morgenstern L. Laparoscopic management of common bile duct stones. A multi-institutional SAGES study. *Society of American Gastrointestinal Endoscopic Surgeons. Surg Endosc* 1994;8:1168-74.
- [21] Cuschieri A, Lezoche E, Morino M, Croce E, Lacy A, Toouli J, et al. E.A.E.S. multicenter prospective randomized trial comparing two-stage vs single-stage management of patients with gallstone disease and ductal calculi. *Surg Endosc* 1999;13:952-7.
- [22] Lu J, Cheng Y, Xiong XZ, Lin YX, Wu SJ, Cheng NS. Two stage vs single stage management for concomitant gallstones and common bile duct stones. *World J Gastroenterology* 2012;18:3156-66.
- [23] Heili MJ, Wintz NK, Fowler DL. Choledocholithiasis: 16. Heili MJ, Wintz NK, Fowler DL. Choledocholithiasis: Endoscopic versus laparoscopic management. *Am Surg* 1999;65:135-8.
- [24] Wu JS, Soper NJ. Comparison of laparoscopic choledochotomy closure techniques. *Surg Endo* 2002;16:1309-13.
- [25] Lange V, Rau HG, Schardey HM, Meyer G. Laparoscopic stenting for protection of CBD sutures. *Surg Laparosc Endosc* 1993;3:466-9.
- [26] Dorman JP, Franklin ME, Glass JL. Laparoscopic CBD exploration b choledochotomy. *Surg Endo* 1998;12:926-8.
- [27] Mir IS, Hajini MF, Rashid T, Sheikh VM, Bhat SN. Laparoscopic management of common bile duct stones: Stent Vs T-tube drainage. *Arch Int Surg* 2016;6:90-5.