

MRI Imaging of Snake Bite Induced Leukoencephalopathy

Dr Parveen Chandna¹, Dr Aditya Duhan², Dr Antriksh Malik², Dr Rohtas K Yadav³, Dr Nithin Narayanan², Dr Vasudha⁴

Senior Resident¹, Junior Resident², Director³, MBBS Intern⁴ Deptt. Of Radio-Diagnosis, Pt.B.D.Sharma Post Graduate Institute Of Medical Sciences, Rohtak, Haryana, India

ABSTRACT

Snake bite has been considered to be a fatal rather than harmful to life with regards to severe adversities in the form of mortality and morbidity in tropical and subtropical countries like India. Aftermath of neurological deficits have been very well postulated following vasculotoxic snake bite which trigger intracranial hemorrhage or subarachnoid bleed commencing due to consumption coagulopathy. In addition to this ischemic strokes and acute disseminated encephalomyelitis have also been detected in some instances. One case of snake bite is hereby reported leading to leukoencephalopathy. Impact of neurotoxins may trigger within minutes extending upto a few hours following inoculation of venom thus causing fatigue, drowsiness, weakness and trauma concerning to blockage of synaptic transmission at either presynaptic or postsynaptic levels. Occasionally, cerebral infarction may not be due to snake bite and may be owing to underlying medical illness.

Key words: Ischemic strokes, leukoencephalopathy, Intracranial hemorrhage, snake, venom

INTRODUCTION

Adverse neurological impact and unique symptoms following a venomous snake bite have been found to be associated with malfunctioning anticoagulant/procoagulant activity or neurotoxicity. Cerebrovascular complications presenting in the form of ischemic strokes in various arterial territories, hemorrhagic stroke including multiple lobar hemorrhages with or without ventricular extension, hemorrhages in subarachnoid and subdural spaces, optic neuritis, epidural hematoma, cerebellar hemorrhage, delayed cerebellar ataxia and disseminated encephalomyelitis have been properly established and being reported. A few patients develop neurological complications associated with cerebral hypoxia which further bears relationship with hypotensive shock that may occur in peculiar snake bite envenomations. Neuromuscular disorders i.e. devouring of the peripheral nervous system generally encompasses following bite of elapids in a similar way as per incidence of a viper bite.^{1,2}

Prospective clinical studies in broad spectrum in Sri Lanka revealed changing scenario in level of consciousness in 80%, autonomic disturbance, anterograde memory loss and delayed neuropathy. Neurological deficits following a viper bite have not been found to be unusual and are usually due to an intracerebral or subarachnoid bleed. It has been estimated rather derived speculations led to the cause that delayed neuropathy could be either due to direct impact of neurotoxins or an adverse reaction to antivenom. Harmful reactions with regards to antivenom show their impact in two shapes at an early stage and later on. Initial reactions reveal steady recovery within 20 to 200 minutes following management and switch on from urticaria to anaphylactic shock. Delayed malfunctionings are noticed in the form of immune complex diseases and exist in the form of serum sickness syndrome usually 5 to 24 days following antivenom administration. Both central and peripheral nervous system manifestations have been observed in association with serum sickness. Generalized myokamia syndrome of continuous and instantaneous muscular activity in consonance to fasciculations especially when snake bite came to notice.^{1,2,3}

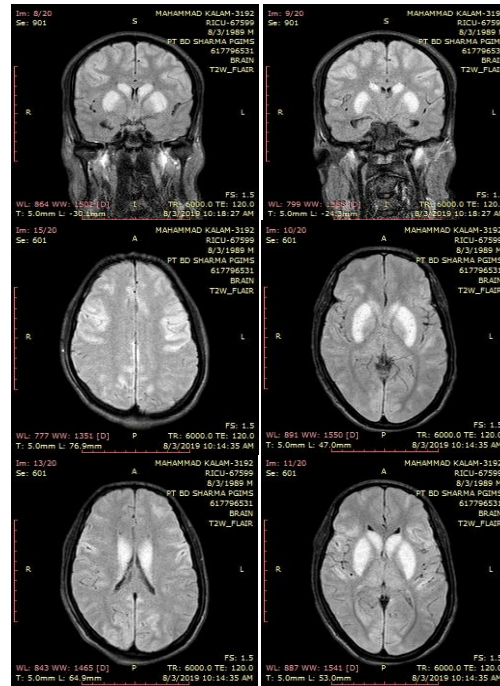
Preparalytic and paralytic stages commensurate due to snake bites. Ptosis, vertigo, blurred vision, hypersalivation and hyperacusis are responsible for preparalytic stage while dominant features of paralytic stage being displayed are progressively paralysed facial muscle, muscles of deglutition and jaw. Respiratory arrest further occurs due to paralysis of intercostal muscles. The suspicious factor related to ischemic stroke in snake bite victims is controversial and still uncertain. The diffuse cerebral malformations may be attributed to toxic encephalopathy owing to toxins in venom. Infarctions are due to the prothrombotic impact of venom and associated with the presence of endothelial damage; this has been supported through the finding revealed as multiple cerebral infarctions in more than 68% of afflictions noticed after snake bite. Moreover, delayed cerebellar ataxia or disseminated encephalomyelitis is most common and bears relationship with immune-mediated malformation triggered by antivenom administration. Neurological features of viperine bite present with symptoms i.e. fainting, drowsiness, confusion, blurred vision,

dizziness, loss of muscle coordination and convulsions. Ischemic strokes involving various arterial territories of the brain, including brain stem and fatal ADEM have also been clearly depicted. Infarction is multifactorial in most of the cases. Altered sensorium after an hour following snake bite is probably related to direct impact of arterial endothelial injuries triggered due to venom itself. Remarkably concerned asymmetrical leukoencephalopathy involving the basal ganglia and thalami (deep nuclei) as well as the cortical rim following snake bite have not been exposed adequately. Although the pathogenesis of leukoencephalopathy has to be further established due to the direct impact of venom which has been seen by us within a few hours of snake bite. Diffuse cortical alterations and infringement of the deep nuclei create probability of posterior reversible leukoencephalopathy syndrome unusually in this cited case; in the same vein. Extrapyrmidal dysfunction of this type has neither been exceptionally explained nor expecting its visualisation in such normal circumstances.^{1,2,3}

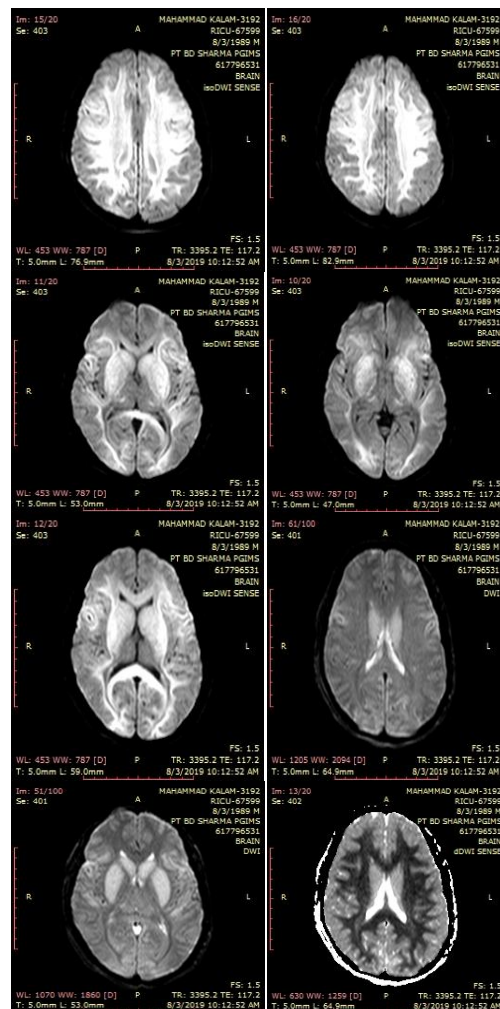
Usually snake bites have been noticed in India especially in the rainy season (June–September). Recognising their fang marks venomous snakes have been classified into five families. In India only three families of snakes namely Viperidae (Vipers), Elapidae (Cobra and Krait) and Hydrophidae (Sea snakes) are commonly encountered. Viperidae, Russell's viper (*Daboia russelli*) and saw scaled viper (*Echis carinatus*), have been recognized as deadly poisonous snakes relating to concern of fatal snake bite in India.

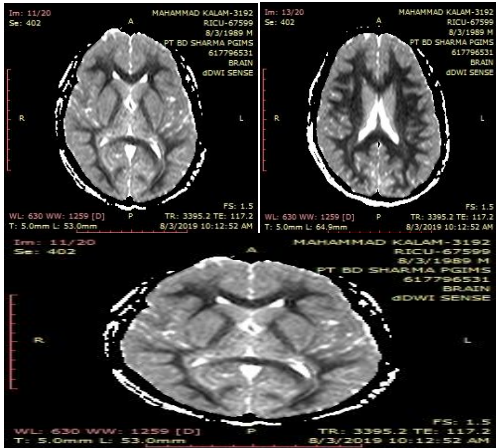
RESULTS

One man aging 30 years was bitten by a venomous snake in the evening hours while he was working in the fields in his village. He was afebrile, the blood pressure was measured at 80/60 mm Hg in right arm supine position and the respiratory rate was as low as 15 breaths/min. At the time of admission in our trauma centre medical emergency ward, he was in the stage of altered sensorium, pulse rate of 106 beats/min with Glasgow Coma Scale (GCS) score of 7 (E₁M₄V₂). He had cellulitis involving the left lower limb. Pupils poorly responding to light. Deep tendon reflexes were curtailed and the detected plantar response was flexor bilaterally. Cardiovascular and respiratory system examinations were normal and the process of micturition was adequate.

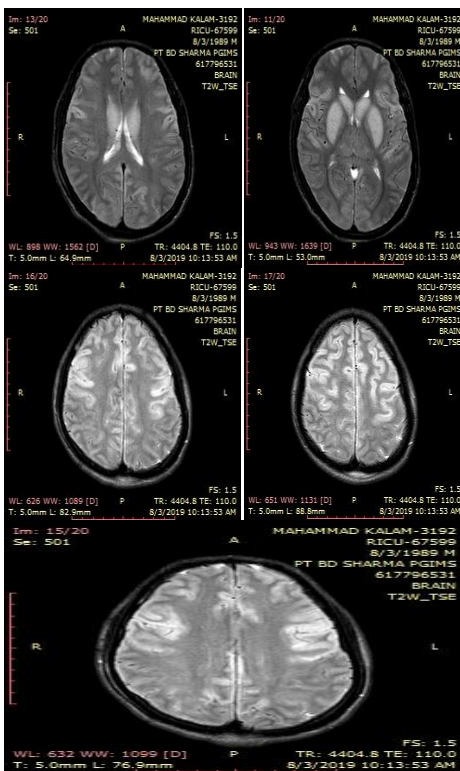


MRI FLAIR IMAGES

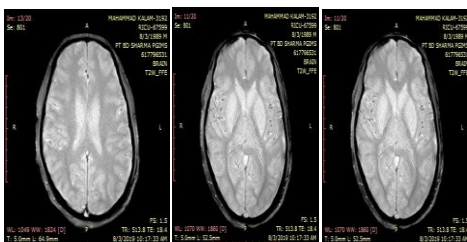




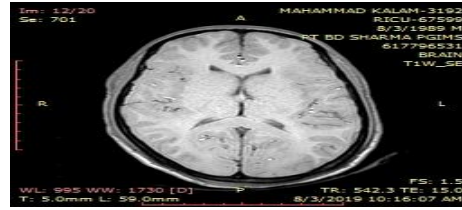
MRI DWI AND ADC IMAGES



MRI T2W IMAGES



MRI FFE IMAGES



MRI T1W IMAGE

MRI images of 30 year old male patient demonstrates Snake bite induced leukoencephalopathy: There is T2 and FLAIR Symmetrical hyperintensities noted in B/L lentiform nuclei , B/L caudate nuclei and B/L Cortical Rim . No E/O blooming on FFE images. There is white matter diffusion restriction on DWI AND ADC images.

DISCUSSION AND CONCLUSION

The proposed etiopathogenesis commences with the presence of venom toxins causing hypercoagulability , immune-mediated vasculitis, endothelial damage and systemic hypotension. The most common and peculiar complication affecting central nervous system is intracranial hemorrhage following vasculotoxic snake bite. Important peculiar and specified disorders include palatal weakness, ophthalmoplegia, limb weakness, ptosis, respiratory failure and neck muscle weakness. Intracranial hemorrhages are related to hemostatic abnormalities i.e. decreased platelets count upto a severe consumption coagulopathy. The common clinical features of viper bite reveal abnormalities local cellulitis, systemic hemorrhagic manifestations due to disseminated intravascular coagulation with deadlock to clotting factors and renal failure. Ischaemic infarction associated with diversion of different arterial territories, including brain stem infarction and acute disseminated encephalomyelitis (ADEM) following viper envenomation have been properly explained.^{2,3}

Acknowledgement

No words can ever express my deep sense of gratitude for my parents & my younger brother, for their affections, endurance, inspiration, support, unending blessings, innumerable sacrifices and unceasing encouragement that has moulded me into the person i am today. the expression of my gratitude's will remain incomplete if i fail to register my deep sense of indebtedness to my family members without whose perseverance and affection it would have not been possible for me to undertake this arduous assignment.

Funding : No funding sources.

Conflict of interest: None declared.

Ethical approval: The study was approved by the Institutional Ethics Committee.

Bibliography

- [1] Seneviratne U, Dissanayake S. Neurological manifestations of snake bite in Sri Lanka. *J Postgrad Med* 2002;48:275–9 .
- [2] Lee BC, Hwang SH, Bae JC, et al. Brainstem infarction following Korean viper bite. *Neurology* 2001;56:1244–5.
- [3] Del Brotto OH, Del Brotto VJ. Neurological complications of venomous snake bites: a review. *Acta Neurol Scand* 2012;125:363–72.