

# Neutralization of Extra And Intra Oral Muscular Forces For Developing Stability In A Complete Denture Prosthesis

Shailesh Razdan <sup>1</sup>, Jasmeen Bhatti <sup>2</sup>, Samad K Kabir <sup>3</sup>

<sup>1</sup>Postgraduate student, Department of Prosthodontics, Sarjug Dental College, Bihar

<sup>2</sup>Postgraduate student, Department of Prosthodontics, IDST, CCSU

<sup>3</sup>Assistant Professor, Department of Prosthodontics, Sarjug Dental College, Bihar

Received Date: 16 June 2021

Revised Date: 18 July 2021

Accepted Date: 06 August 2021

## ABSTRACT

Oral environment includes physical, chemical, thermal, mechanical, and even biohazardous factors in which a restorative material must survive. For complete denture prosthesis, though, the main challenges are physical in nature, out of which the most significant are the muscular forces. The tongue can either enhance denture adaptation or lead to denture rejection. This case of an elderly female patient reports one such case in which the mandibular dentures were earlier rejected; Chief problems included gagging, denture intolerance, which was overcome by patient education, motivation, and the incorporation of the neutral zone within the complete mandibular denture. As compared to conventional methods, we present a method in which the neutral zone was recorded prior to tentative jaw relation recording. The material used in this case was a heat cure soft liner, that holds ideal properties in terms of dimensional stability over a period of time.

**Keywords** – dead space, resilient liners, neutral zone, complete denture, elastomeric impression materials

## INTRODUCTION

The tongue is one of the most dominant muscular organs of the oral cavity, which has a base that is fixed and the other end as free, thus giving it the abilities of a spring like action. Muscles generally have an antagonist muscle, which counters or synergizes the action of the muscle. The tongue is so dominant that to oppose its action in the oral cavity, there are 14 to 16 bilateral muscle groups to counter it. <sup>1</sup> An essential application of muscle physiology in the construction of the complete denture prosthesis has been to identify the forces exerted by these muscles on either side. While different methods have been used to enhance retention and stability in complete denture prosthesis, <sup>2</sup> recognition of a dead space or neutral zone has been instrumental in enhancing denture stability. <sup>3</sup> NZ is basically a space that is occupied by natural/artificial teeth where the conflict between the muscles seems to be minimized. <sup>4</sup> different methods have been described in the literature to record NZ that ranges from various techniques <sup>5, 6</sup> to the use of various materials. <sup>7-9</sup> While most of the techniques employ recording of the neutral zone during the

recording of jaw relations, this article presents a new approach in which the neutral zone is recorded and verified in a single appointment. The article describes the technique of recording NZ using the mechanical retentive feature for self cure soft liner.

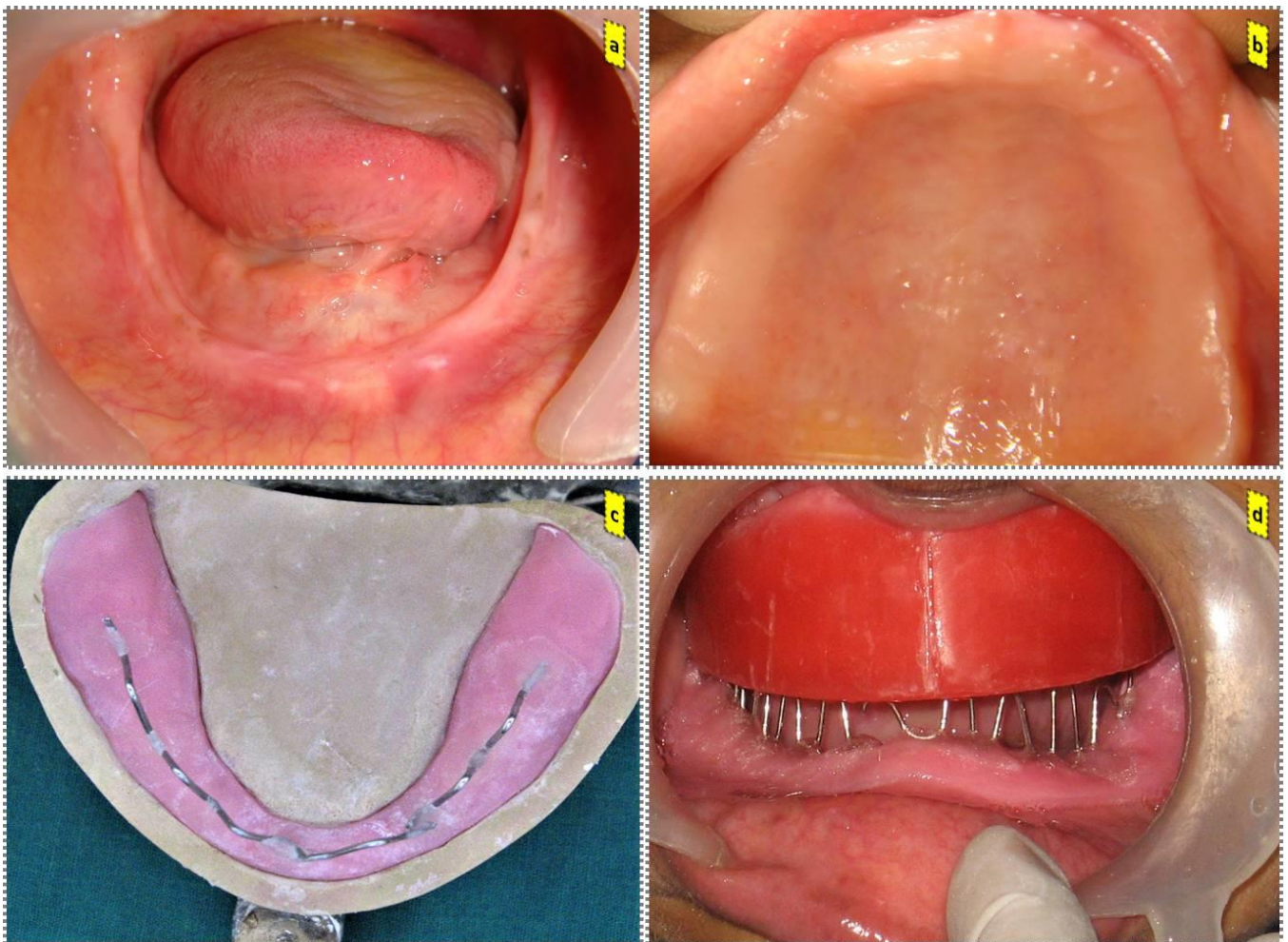
## CASE REPORT

An elderly female patient in his early sixties reported to the undergraduate section of the Department of Prosthodontics with a chief complaint of denture intolerance. The patient reported that she was not able to wear the dentures, especially the mandibular denture, and would always feel like vomiting. The patient was transferred to the post-graduate wing of the department, and on the first day, a detailed history was recorded. Medical history was non-contributory, while social history revealed that she was a school teacher by profession. Dental history disclosed that the patient has been completely edentulous for the last 1 year and had got the denture fabricated 9 months back but was unable to wear the mandibular denture. The patient also disclosed that for an esthetic reason, she was wearing the maxillary denture regularly. The existing denture was graded as fairly good in terms of design and construction. Extraoral examination did not disclose any negative clinical findings, while intraoral examination revealed a well-formed mandibular (**Fig 1a**) and maxillary residual alveolar ridge (RAR) (**Fig 1b**). Most of the other intraoral features were within normal limits, including the size, position of the tongue, and associated structures. When asked to wear the mandibular denture, the patient would start vomiting within one minute of denture wearing, while the denture was also thrown out by initial movements of the lips and cheeks. Upon close observation, it was noted that the denture would get destabilized before the patient would start gagging. Destabilization was initiated by speech, and after becoming unstable, the denture would move posteriorly to initiate gagging. The patient was informed about the problem and was presented with various treatment options that included implant-supported fixed complete denture for both maxillary and mandibular arches; implant-supported overdenture with a minimum of two or more than two implants. The patient enquired and requested for an economically viable treatment option



which was the construction of a conventional complete denture with the location of the neutral zone and psychotherapeutic counseling regarding the management of gagging. During clinical procedures, it was noted that the patient did not have the tendency to gag during impression making or insertion of denture bases. For complete denture treatment, routine clinical and laboratory procedures were performed till the jaw relation stage. The mandibular trial denture base was modified, and a 19 gauge stainless steel orthodontic round wire (Pigeon Dental stainless steel, India), was incorporated within the denture base (**Fig 1c**). Maxillary occlusal rims were adjusted for vertical dimensions, while for the mandibular arch, the trial denture base was first adjusted for occlusal clearance (**Fig 1d**), which was followed by placement of self-cure resilient denture liner (Fortex; Lucite Intl, Durham). The patient was educated and instructed about the type of functional muscular movements she was supposed to make while the material was set. Once the material was set, all excess was removed, and the fit was determined on the cast (**Fig 2a**). No adjustment was done on the labial, buccal and lingual surfaces of the liner. A putty (Reprosil, Dentsply/Caulk; Milford, DE, USA) index was then made over the recorded labial, buccal and lingual surfaces, and the index was preserved for future use. The

soft liner was removed, and modeling was (Moyco Industries, Inc, Philadelphia, PA) then heated and poured within the putty index adapted on the denture base. The putty index that was previously prepared transferred the contours within the mandibular occlusal rims (**Fig 2b**). the jaw relation recording was then completed on the patient (**Fig 2c**). Artificial teeth (DPI, India) were arranged, and a denture trial was done (**Fig 3a**). The occlusal scheme incorporated within the new denture was bilateral balanced occlusion. The denture was processed (**Fig 3b**) and the final clinical steps were performed (clinical remounting), and the denture was inserted. During all previous appointments, patients' threshold to gagging was decreased through education and motivation while using the technique of distraction whenever the need arose. The patient was put on a one-year follow-up protocol (24 hours, one week, one month, and then every six to twelve months). Patient's apprehensive gagging problem was overcome through education, while the incorporation of NZ within the denture enhanced stability of dentures which in turn prevented gagging. The patient was highly satisfied with the outcome of the present denture (**Fig 3c**). Instructions regarding the use of the denture were reiterated at each follow-up during visits.



**Figure 1: (a) and (b) Mandibular and Maxillary completely edentulous arch (c) Mandibular temporary denture base with metal retainers (d) mandibular arch with retainers inside the patient oral cavity**

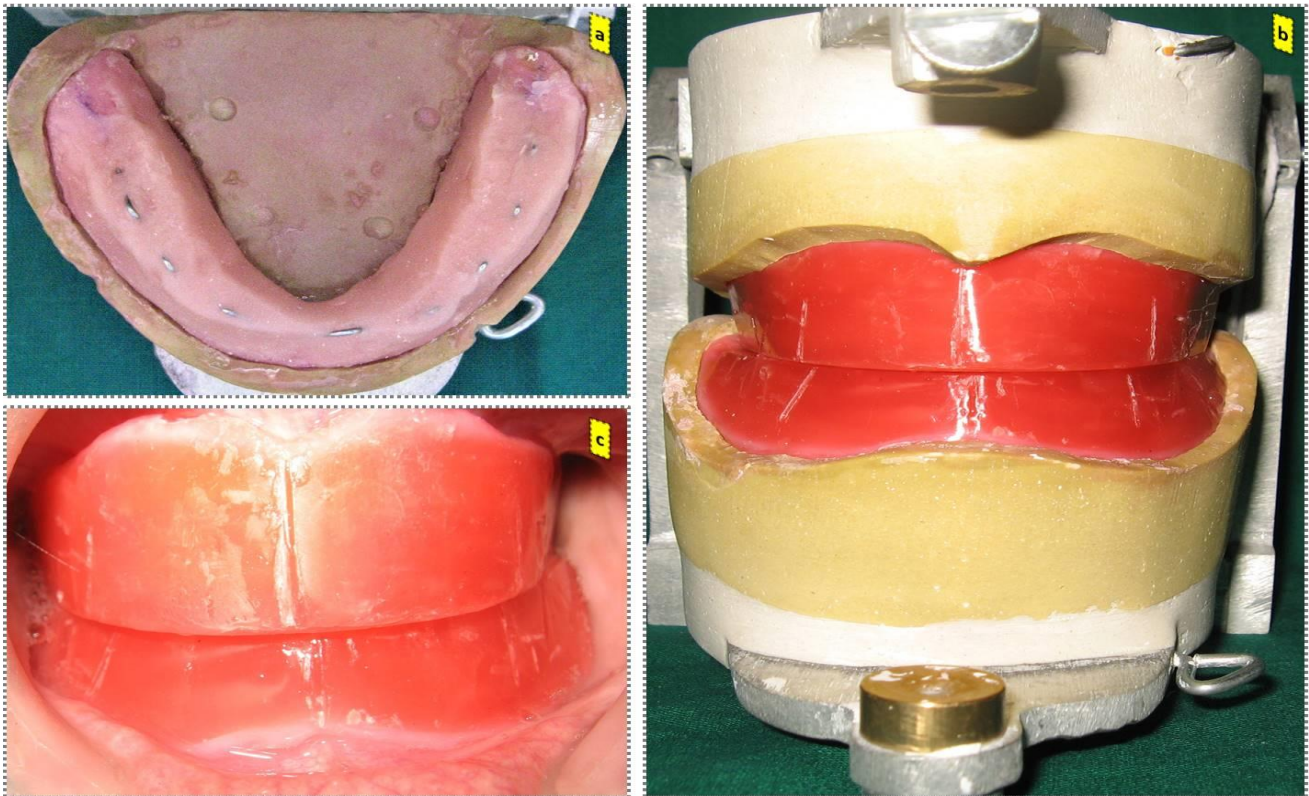


Fig 2: (a) Neutral zone recorded for mandibular arch (b) Mandibular and Maxillary occlusal rims on a mean value articulator (c) Mandibular arch during the recording of jaw relations

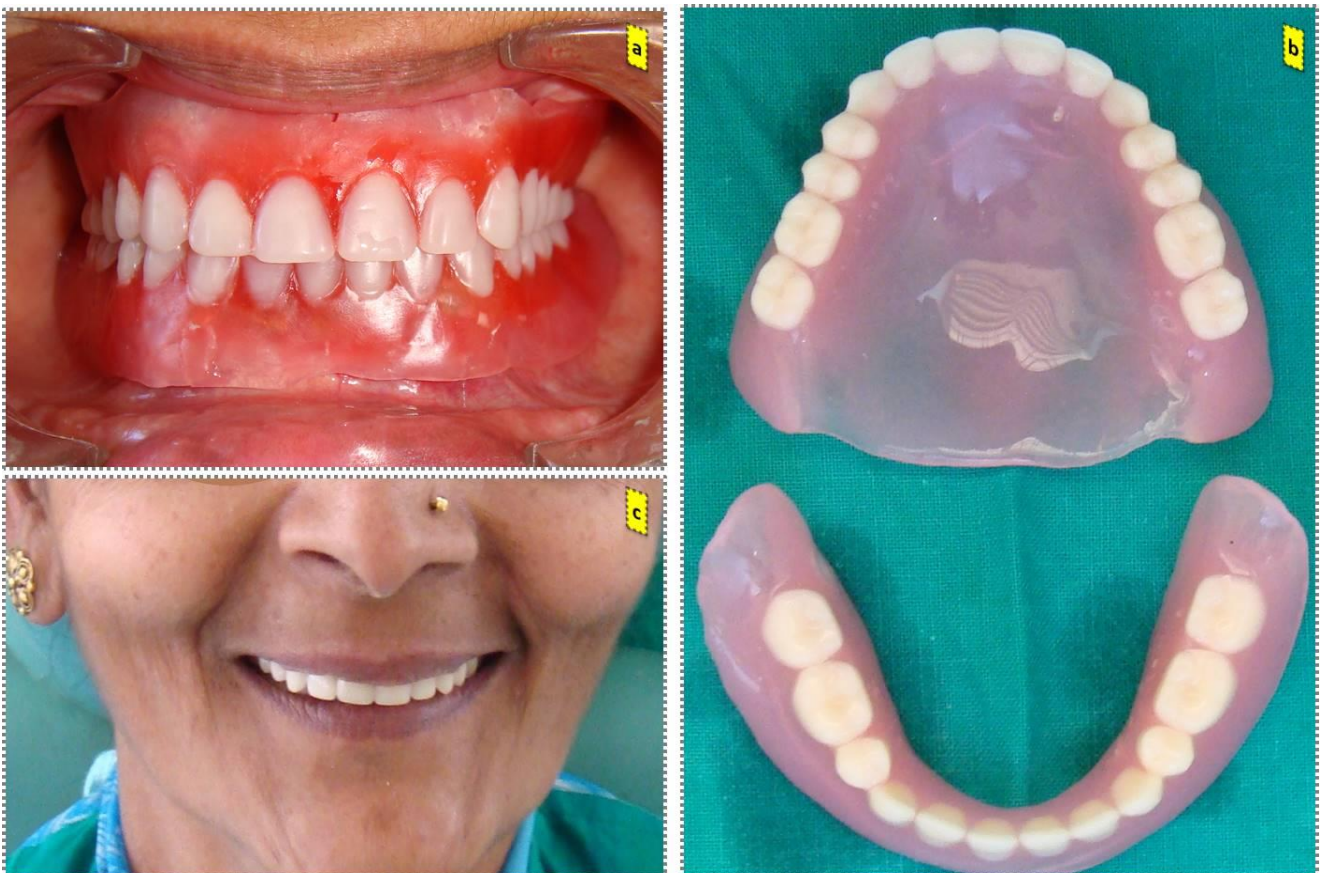

Figure 3: (a) trial denture (b) processed complete denture prosthesis (c) Final complete denture in the patient's mouth.

## DISCUSSION

This article, in the form of a clinical case report, presents a case of the incorporation of the neutral zone space within the denture at a stage that provides additional benefits than the conventional technique. The unique advantage is that the whole process can be completed within the same appointment, and it also allows to verify the efficiency of recording of NZ at the time of jaw relations. The two advantages are mainly achieved by the approach as well as the material used. Although the material used has certain inherent problems when used as a denture liner, the same drawbacks do not apply if and when it is used as a NZ recording material. Heat cure denture-based liner has been used earlier,<sup>9,10</sup> however, this technique does not use the posterior support that is provided by self-cure acrylic resin.

Effectiveness of a particular technique requires locating the areas of concern according to the individual's anatomy and his particular way of functioning.<sup>11,12</sup> This is particularly true in complete denture fabrication. A general approach to all complete dentures for all patients makes every denture a monotonous entity rather than an individually fabricated prosthesis. Pressures within the neutral zone are not as easy to measure as pressures applied to the basal seat of the denture.<sup>13</sup> With clinician having no control over the tongue of the patient either directly or indirectly through the prosthesis,<sup>14</sup> it is imperative to respect the forces exerted by this muscular organ which is also mainly responsible for its oral stereognosis ability.<sup>15</sup>

According to Dawson,<sup>16</sup> any orthodontic treatment that does not respect the tongue is bound to fail even if the teeth are deeply embedded within the bone. Tongue will dislodge the denture if it encroaches, and the main encroachment is due to the position of artificial teeth that they occupy within the denture. The forces can be more during stereognosis functions of the tongue.<sup>15</sup>

With the recording of NZ, the buccal/labial/lingual musculature contours adapt physiologically against a developed contour within the denture flanges. This feature aids in stability and retention. Denture surfaces (polished) for mandibular denture must allow the surrounding oral musculature to readily adapt according to their individual contours.<sup>17,18</sup>

## CONCLUSION

The technique described is simple, inexpensive, and less time-consuming and can be easily incorporated into dental

practice. The technique can also be taught to dental students in dental schools at minimal expenses.

## ACKNOWLEDGEMENTS

The authors would like to thank the staff of the dental laboratory for their meticulous work.

## REFERENCES

- [1] Lindeman DE, Moore RN. Measurement of intraoral muscle forces during functional exercises. *Am J Orthod Dentofacial Orthop.* Apr;97(4) (1990) 289-300.
- [2] Rathi N, Mattoo KA. Artless solution to resolve the problem of retention in resorbed alveolar ridge cases. *WebmedCentral Rehabilitation.*, 5 (9) (2014) 1-6: WMC004709.
- [3] Brill N, Tryde G, Cantor R. The dynamic nature of the lower denture space. *J Prosthet Dent* (1965) 15:401-18.
- [4] Glossary of Prosthodontic terms. (2005) 8th ed. *J Prosthet Dent* 94:46
- [5] Fish EW. Using the muscles to stabilize the full lower denture. *J Am Dent Assoc.*, (1933) 20:2163–2169
- [6] Rathi N, Rahman S, Mattoo K. Creating oral musculature balance in a complete mandibular denture. *Int J Med Rev Case Rep.*, 4(7) (2020) 8-9.
- [7] Lott F, Levin B. Flange technique, an anatomic and physiologic approach to increased retention, function, comfort, and appearance of the denture. *J Prosthet Dent* (1996) 16:394-413
- [8] Beresin VE, Schiesser FJ. The neutral zone in complete dentures. *J Prosthet Dent.*, Oct;36(4) (1976) 356-67.
- [9] Rathi N, Yunus N, Mattoo KA. Technique for Recording Neutral Zone with a Soft Liner. *J Clin Res Dent* (2019) 2 :1-2
- [10] Beresin VE, Schiesser FJ. The neutral zone in complete dentures. *J Prosthet Dent.*, (2006) 95:93–101.
- [11] Singh V, Jain P, Mattoo KA. Immediate Complete Denture With A Denture Try In – Case Report. *SSRG International Journal of Medical Science.*, 6 (11) (2019) 22-23
- [12] Starcke EN. The contours of polished surfaces of dentures- A review of literature. *J Am Dent Assoc.* (1970) 81:155–60.
- [13] Kumar L , Mattoo KA, Yunus N, Singh M, Yadav A. Comparative evaluation of pressure produced on maxillary denture bearing areas by different impression techniques-an in vivo study. *Int J Oral Health Sci Adv* (2015) 3: 38-43
- [14] Fahmi FM. The position of the neutral zone in relation to the alveolar ridge. *J Prosthet Dent.* (1992) 67:805–9.
- [15] Singh V, Mattoo KA. Oral Stereognosis pattern in patients with dental prosthesis in the elderly population. *Int J Clin Exp Physiol* (2014) 1 : 211-15.
- [16] Dawson PE., *The envelope of function. Functional occlusion from TMJ to smile design*, 1st edn. Mosby Elsevier, Canada, (2007) 141–148
- [17] Matthews, E. The polished surfaces. *Br Dent J* (1961) 5:407–411.
- [18] Kapoor A, Singh M, Mattoo KA. Abridged duplication of palatal rugae for complete denture prosthesis. *SSRG International Journal of Medical Science.*, 6 (11) (2019) 1-2.